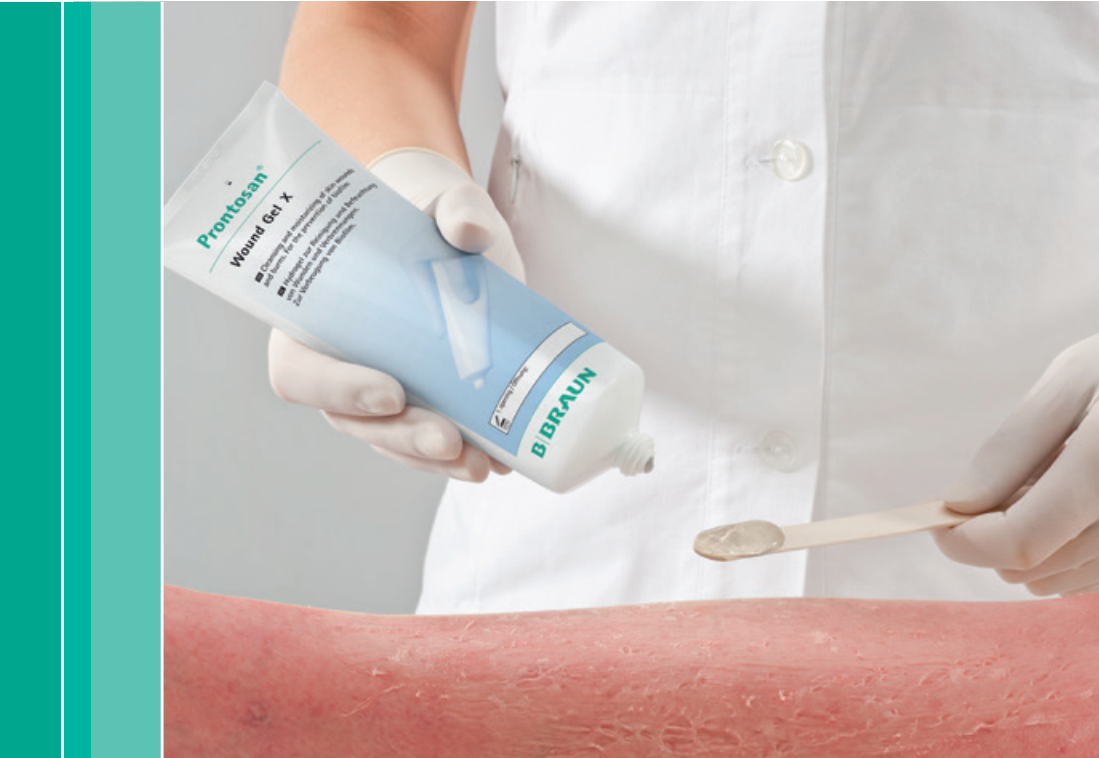

# Prontosan® Case Studies



CoE Infection Control



**B | BRAUN**  
SHARING EXPERTISE



# Introduction

Since the launch of Prontosan® Wound Irrigation Solution and Prontosan® Wound Gel, reports have been reaching us of sensational treatment successes. We would like to share these with you today in the form of a short photo storyboard.

In the meantime the products have become available throughout the world and have already successfully benefited tens of thousands of patients suffering from chronic wounds. Due to its special Betaine formulation in particular, Prontosan® facilitates more efficient removal of coatings and biofilm from wounds, which considerably reduces both duration of therapy and cost implications for healthcare services.

Use of Polyhexanide as a preservative means the bottle can be used for up to eight weeks after it is first opened.

We would like to take this opportunity to thank all the doctors, nursing staff and B. Braun employees\* for forwarding the material to us and helping us put the picture book together.

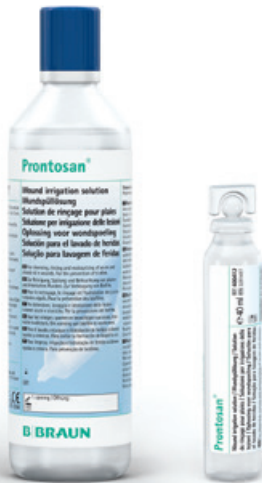**B. Braun Medical AG**  
CoE Infection Control

Sempach, Switzerland  
March 2011

\* Australia, Belgium, Czech Republic, Germany, Hungary, Italy, Spain, Sweden, Switzerland, United Kingdom, Holland

# Introduction

## Prontosan® Wound Irrigation Solution



Prontosan® is a ready to use solution containing 0.1% Polyhexanide (preservative) and Betaine (surfactant) in water for:

- the release of fibrin coatings and debris from the wound in a way that protects tissue
- absorption of wound odours
- usage up to 8 weeks after opening
- cleansing and moistening of acute and chronic wounds, 1<sup>st</sup> and 2<sup>nd</sup> degree burns
- keeping wounds and wound dressings moist

### PAINLESS DRESSING CHANGES WITH PRONTOSAN®

Dressings are often encrusted and stick to wound surfaces. If attempted to be removed from the wound surface when dry, new injuries often arise with the additional risk of infection, which in turn delay the healing process. In cases where bandaging is difficult to release, intensive moistening of the dressings with Prontosan® Wound Irrigation Solution is advisable until they can be gently released without traumatising the wound surface. If stubborn large encrustations are present, the whole section of the body including the dressing should be thoroughly saturated with Prontosan® Wound Irrigation Solution until the dressings can be easily released.

### Betaine

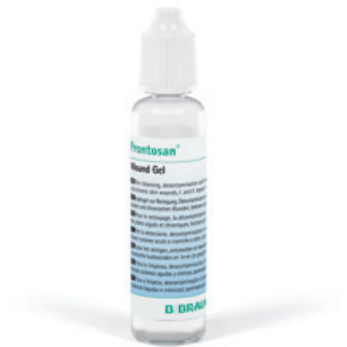- particularly high quality tenside
- effective wound irrigation
- excellent skin tolerance
- complete absence of regreasing compounds
- skin and mucous membranes are not affected and do not dry out
- exemplary record in the cosmetics industry

### Polyhexanide

- excellent skin tolerance
- skin and mucous membranes do not dry out
- no irritations
- non-toxic
- high tolerability
- hypoallergenic
- no tissue irritation
- no resorption



## Prontosan® Wound Gel

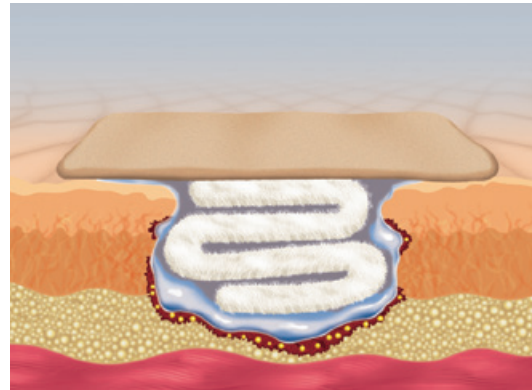


Prontosan® Wound Gel is a ready to use gel containing 0.1% Polyhexanide (preservative) and Betain (surfactant), Glycerol (moisturizer) and Hydroxyethylcellulose (gelling agent) in water for:

- cleansing, decontamination and moistening of acute and chronic wounds, 1<sup>st</sup> and 2<sup>nd</sup> degree burns
- absorption of wound odours
- does not inhibit granulation and epithelialisation

### HINTS AND TIPS

All wounds should, in principle, first be rinsed and cleansed with Prontosan® Wound Irrigation Solution, Prontosan® Gel and Gel X remains on the wound until the next dressing change. It therefore has a long acting effect.



For the application in deep or tunneling wounds, wound cavities and difficult to access areas, cover the incrustrated tissues with a 3–5 mm layer of **Prontosan® Wound Gel** and cover with a secondary bandage.

# Introduction

## Prontosan® Wound Gel X

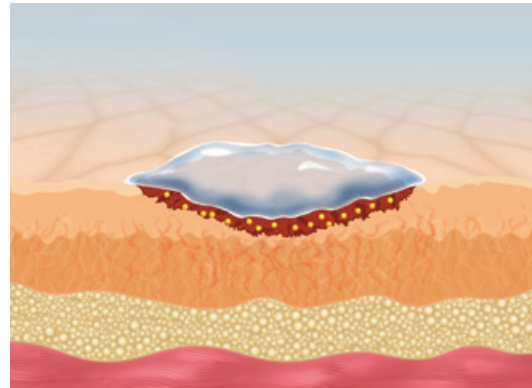


Prontosan® Wound Gel is a ready to use gel containing 0.1% Polyhexanide (preservative) and Betain (surfactant), Glycerol (moisturizer) and Hydroxyethylcellulose (gelling agent) in water for:

- cleansing, decontamination and moistening of acute and chronic wounds, 1<sup>st</sup> to 4<sup>th</sup> degree burns
- absorption of wound odours
- does not inhibit granulation and epithelialisation

### HINTS AND TIPS

All wounds should, in principle, first be rinsed and cleansed with Prontosan® Wound Irrigation Solution, Prontosan® Gel and Gel X remains on the wound until the next dressing change. It therefore has a long acting effect.



In large surface area wounds apply a 3-4 mm thick layer of the **Prontosan® Wound Gel X** and cover with a secondary bandage.

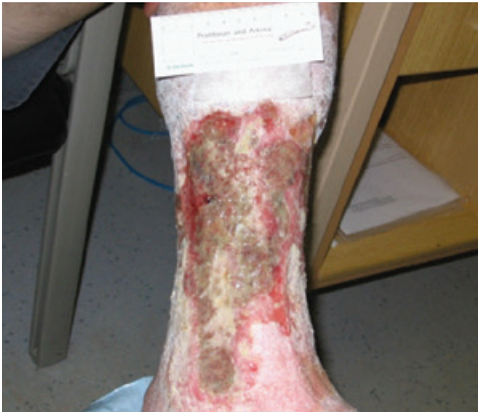# Content

## Prontosan® Case Studies by wound type

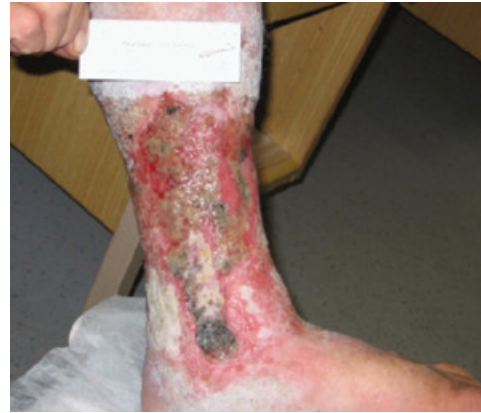Venous Leg Ulcers .....	8 – 27
Traumatic Wounds .....	28 – 41
Pressure Ulcers .....	42 – 49
Burns .....	50 – 53
Post-Operative Wounds .....	54 – 57
Diabetic Ulcer .....	58 – 59
Others .....	60 – 71

# Venous Leg Ulcer

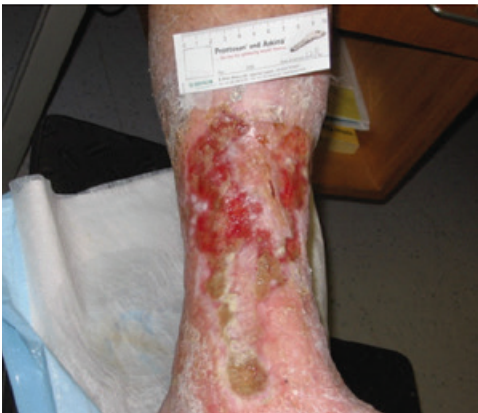Responsible person for treatment	Matthew Dutton, Wound Care Clinical Nurse Consultant
Institution	The St. George Hospital, Kogarah, NSW, Australia
Gender (female, male)	Male
Age of patient (year)	1930
Past medical history (PMH)	Venous leg ulcers
Medical treatment	–
Allergies	–
Wound diagnosis	Venous ulcers of the right leg (Ankle Brachial index of 0.95), covered with 95% thick green sough, highly offensive odour. Poor quality of life recorded from admission by Mr AR (patient), who had to cover his leg with a plastic bag in order to eat his Meals due to the odour.
Localisation of wound	Right lower leg
Age of wound	–
Previous treatment of wound	None
Reason for treatment change	–
Dressing change frequency	Daily
Other products used	The patient received a quick resolution of odour and wound pain in his venous ulcers. The dramatic improvement in wound healing began however, in combination with the correct antibiotic regime and compression bandaging.
Outcome (final comment)	Use of Prontosan® for this patient prevented an inpatient stay in Hospital, which did not put undue strain on health care resources. After beginning Prontosan® Application, the Patient no longer needed to cover his wound with bag, due to effectiveness of Prontosan® absorbing wound odours – resulting in improved Quality of Life outcome.



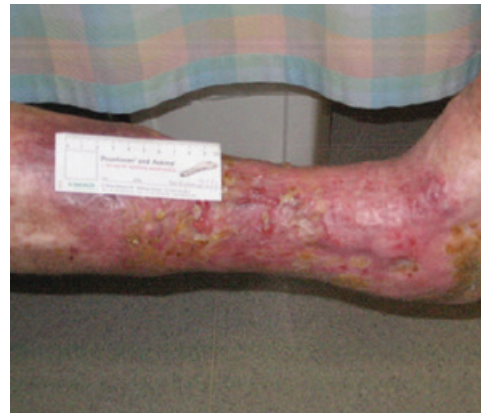Day 1  
Covered with 95% thick green sough, highly offensive odour, high purulent exudate and a macerated peri-wound.



Day 7  
At this stage the odour in the wound had decreased significantly, as had the pain. The exudate levels remained high and purulent.



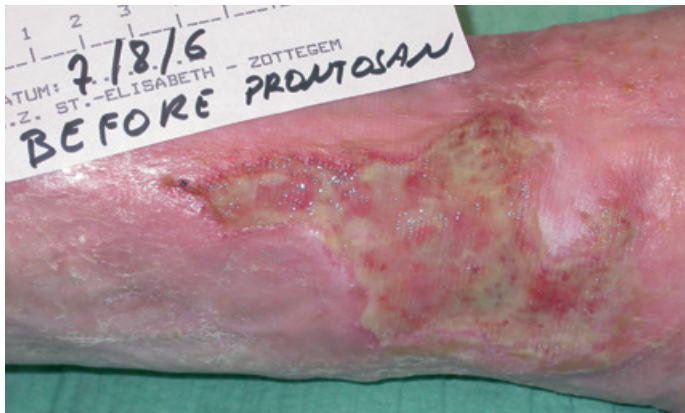Day 12  
The combination of right wound cleansing regime, right antibiotic and compression bandaging aided in a rapid increase in wound improvement with a change to mild serous exudate.



Day 259  
Antibiotics were ceased at day 36 and **Prontosan®** was ceased at day 90 when the wound was close to complete healing. However, shortly after ceasing the Prontosan™ the patient developed another infection and deterioration in the lower limb.

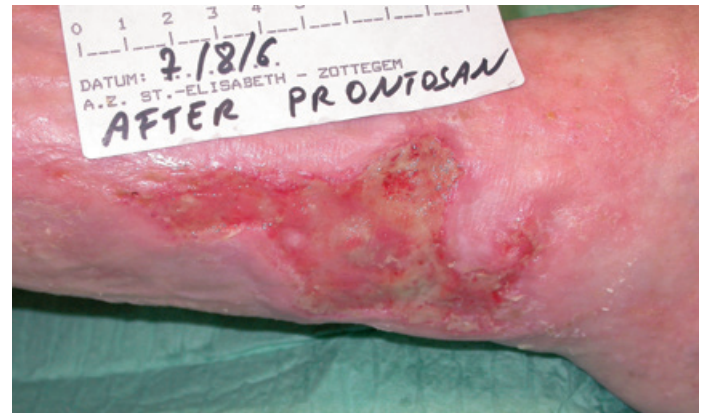# Venous Leg Ulcer

Responsible person for treatment	Frans Meuleneire
Institution	AZ St Elisabeth, Zottegem, Belgium
Gender (female, male)	Female
Age of patient (year)	1925
Past medical history (PMH)	–
Medical treatment	–
Allergies	–
Wound diagnosis	Venous leg ulcer contaminated with MRSA
Localisation of wound	External leg on the left
Age of wound	3 years
Previous treatment of wound	–
Reason for treatment change	No progress using saline solution for wound cleansing. Presence of MRSA
Dressing change frequency	3 x weekly
Other products used	Cutisorb®, Sorbact®



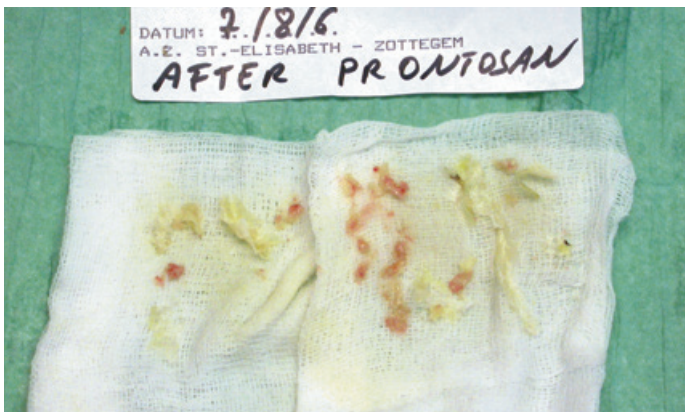07.08.2006

Wound edges are epithelialised but wound surface is sloughy and fibrin coating is hard to remove.



07.08.2006

Remarkably cleaner wound surface after 10 minutes.



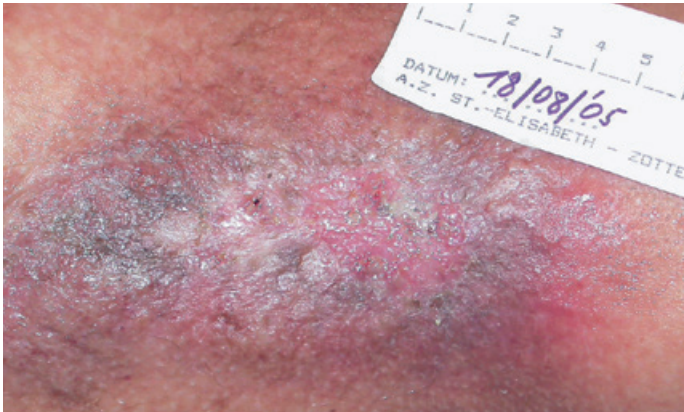
07.08.2006

Gauzes soaked in Prontosan® Wound Irrigation Solution have been left on the wound for 10 minutes.

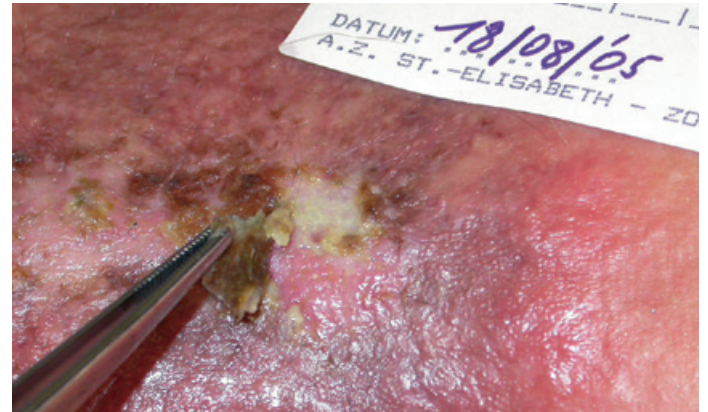# Venous Leg Ulcer

Responsible person for treatment	Frans Meuleneire
Institution	AZ St Elisabeth, Zottegem, Belgium
Gender (female, male)	Female
Age of patient (year)	1931
Past medical history (PMH)	–
Medical treatment	–
Allergies	–
Wound diagnosis	Venous leg ulcer
Localisation of wound	–
Age of wound	3 years
Previous treatment of wound	Braunol® tulle
Reason for treatment change	Removal of crusts was impossible without traumatising the wound surface
Dressing change frequency	Once daily
Other products used	–

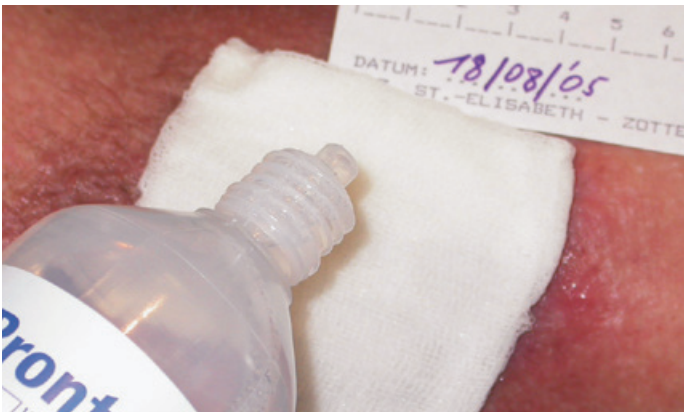



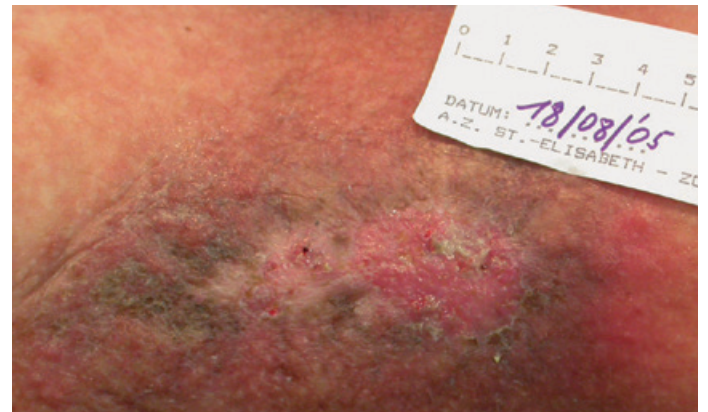18.08.2006  
Encrusted wound with risk of infection.



18.08.2006  
After 10 minutes removal of wound crusts.



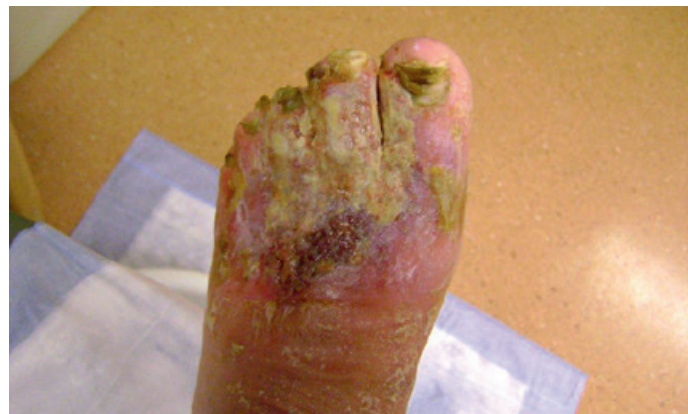18.08.2006  
Prontosan® Wound Irrigation Solution applied on a gauze.



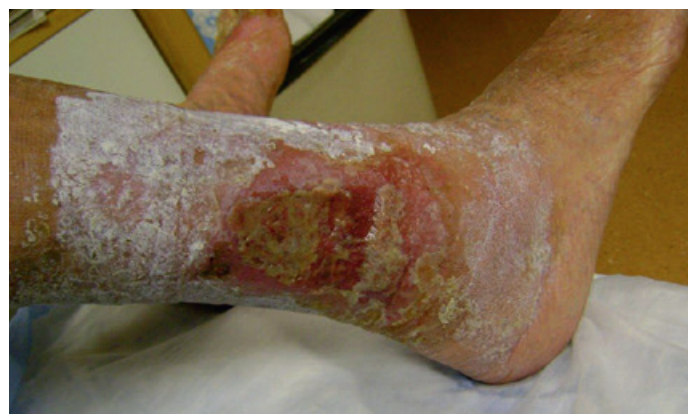18.08.2006  
Clean wound and no signs of infection.

# Chronic bilateral lower leg wounds

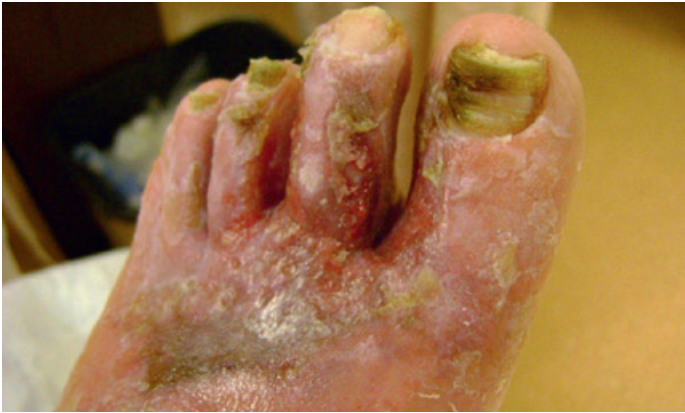Responsible Person for Treatment	Dr. Allison Jerome
Institution	Choice Day Program, Edmonton, Canada
Gender (female, male)	Female
Age of patient (year)	1934
Past medical history (PMH)	Chronic venous insufficiency with bilateral lower limb wound and cellulites, MRSA/Pseudomonas, atrial fibrillation, chronic pain, anemia
Medical treatment	-
Allergies	Penicillin, Sulfa
Wound diagnosis	Chronic bilateral lower leg wounds
Localisation of wound	Right and left lower legs and top of right foot. Large ulcer to the dorsum of the left foot and toes
Age of wound	5 years
Previous treatment of wound	Soaks with vinegar and/or sterile water, intrasite gel, Aquacel® AG, Acticoat™, Acticoat™ Flex 3, Kalostat®, Xtrasorb plus®, Mesorb®, Mepilex®, Comprilan®, SurePress® with Tubigrip™
Reason for treatment change	Infection, exudate, increased pain
Dressing change frequency	3 times a week
Other products used	Mepilex® AG, Xtrasorb®, Abdominal pads, SurePress®, Comprilan®, Mepilex® transfer, Mepilex®, Mesorb®, conforming bandage, Tubigrip™
Outcome (final comment)	The patient was a candidate for amputation or plastic surgery grafts of the lower limb. Du to Prontosan® this was not needed.



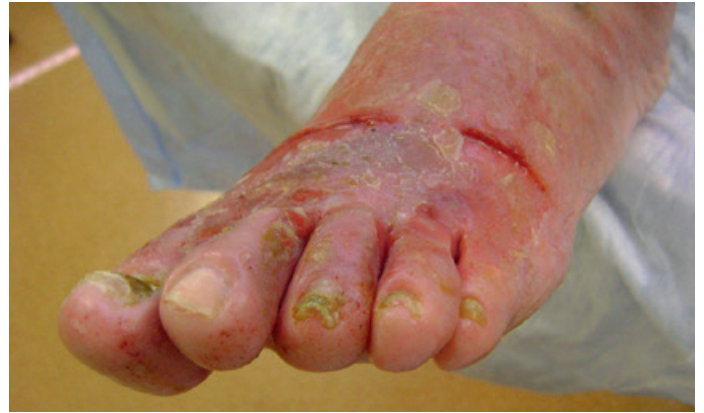19.07.2011



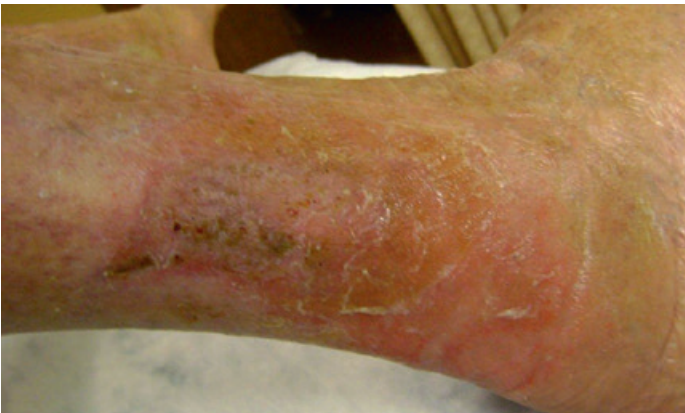19.07.2011



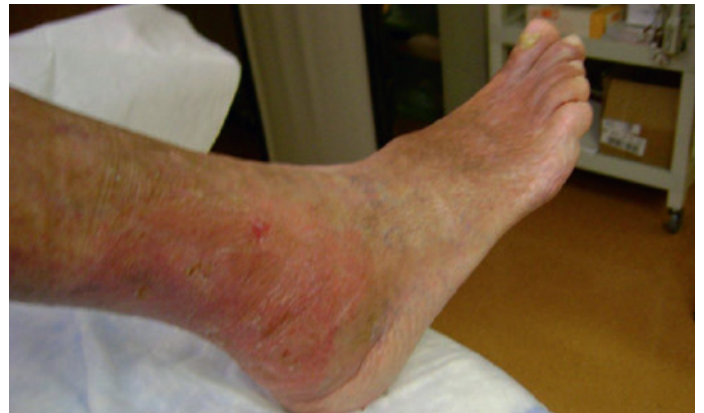15.08.2011



26.08.2011



15.08.2011

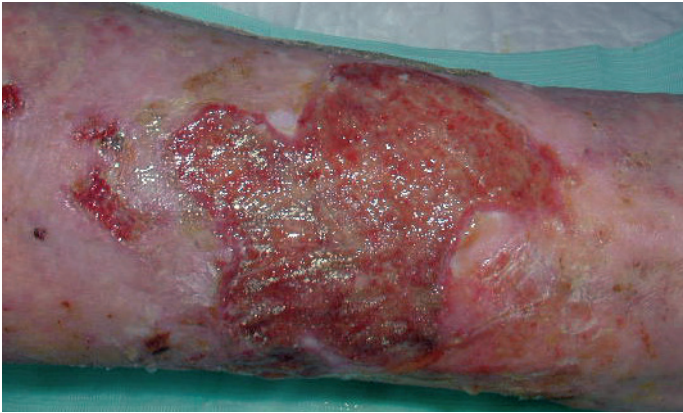

26.08.2011

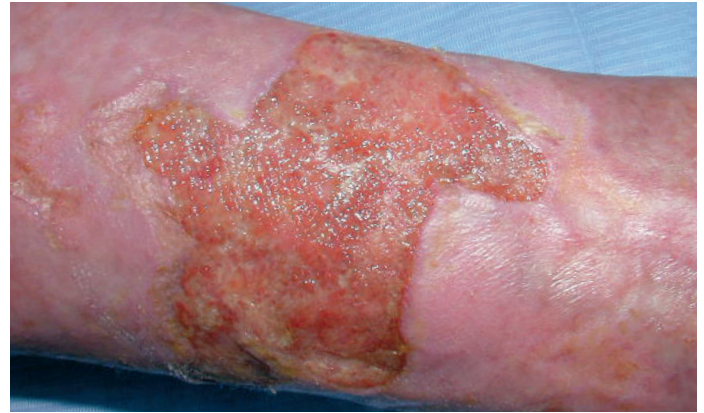# Venous Leg Ulcer

Responsible person for treatment	Jana Samarantská
Institution	Gerontology dpt., Pardubice, Czech Republic
Gender (female, male)	Female
Age of patient (year)	1940
Past medical history (PMH)	Venous insufficiency after allergic reaction, hypertension
Medical treatment	–
Allergies	Polyvalent allergy
Wound diagnosis	Oedema, inflammation, pain
Localisation of wound	Around the right lower extremity
Age of wound	1 year
Previous treatment of wound	Alginate + Ag, Polyurethane foam + Ag, Dermacyn®
Reason for treatment change	–
Dressing change frequency	–
Other products used	Initially use of Dermacyn® - without efficacy
Outcome (final comment)	Elimination of pain achieved by rinsing with Prontosan® Wound Irrigation Solution only

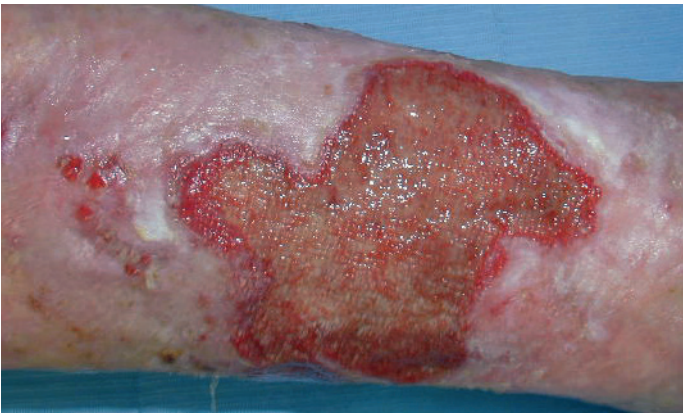



18.04.2005  
Malodorous, painful and hypergranulated wound.  
Allergic reaction of the surrounding skin. Rinsing with Dermacyn®.



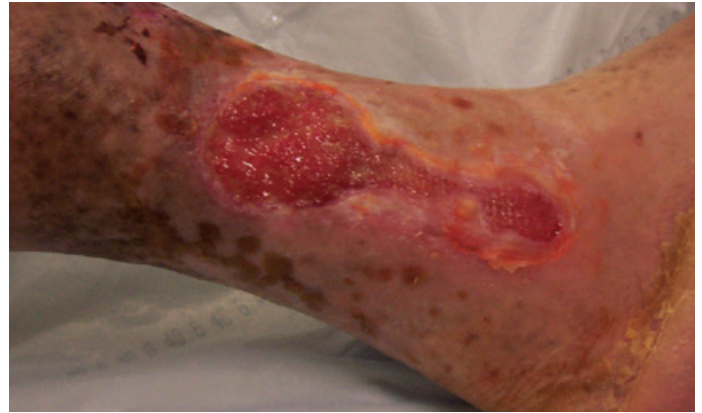12.05.2005  
Clean condition of the wound after 14 days. No pain, no hypergranulation and ceased allergic reaction. Size is decreasing.



28.04.2005  
Inflammation, hypergranulation. Wound grows *Staphylococcus aureus*, *Proteus mirabilis*, *Enterococcus faecalis*. Antibiotic treatment.  
Rinsing with Prontosan® Wound Irrigation Solution after 8 hours.

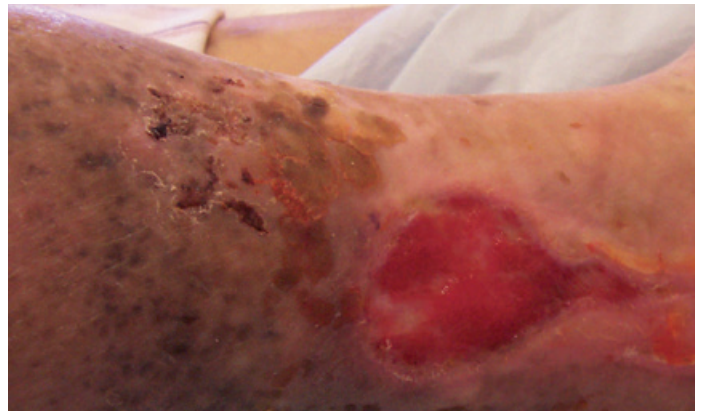# Venous Leg Ulcer

Responsible person for treatment	Mrs. Ibolya L.
Institution	Szeged, Hungary
Gender (female, male)	Male
Age of patient (year)	1930
Past medical history (PMH)	Chronic crural ulcer, insufficiency of the venous system
Medical treatment	None
Allergies	None
Wound diagnosis	Serous, slightly purulent encrustation of the wound, crural oedema, pain
Localisation of wound	Right leg and intramalleolar region
Age of wound	Several years
Previous treatment of wound	Dry bandage
Reason for treatment change	Superinfected, stagnating wound
Dressing change frequency	Twice daily during the first week, once a day thereafter
Other products used	During the last week: Grassolind® (paraffin-impregnated net)
Outcome (final comment)	Healed wound



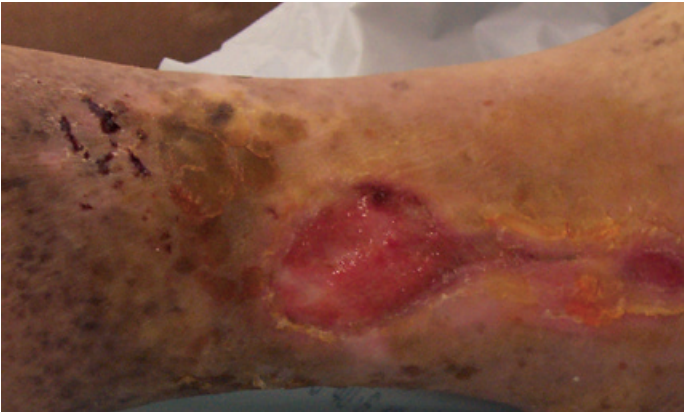21.07.2006

Crural oedema, serous, slightly purulent discharge, crural itchiness, pain.

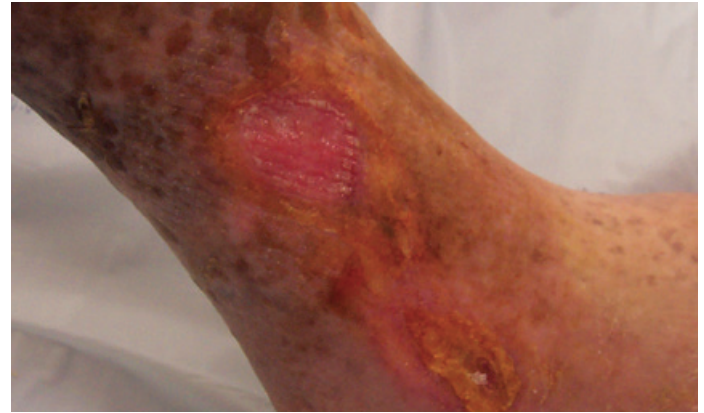

27.07.2006

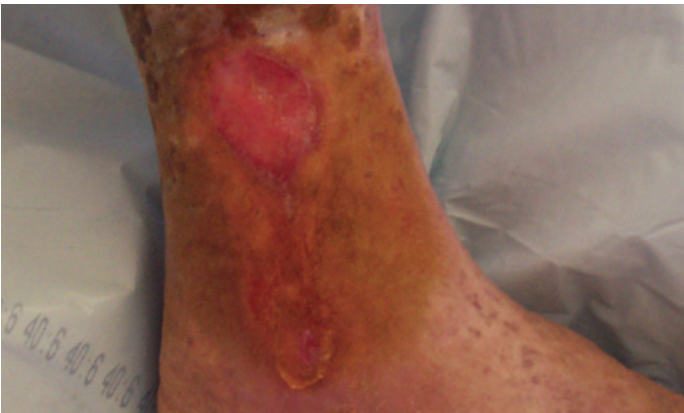The infected ulcer has cleaned up; slight, serous discharge.



02.08.2006  
The granulation has started.



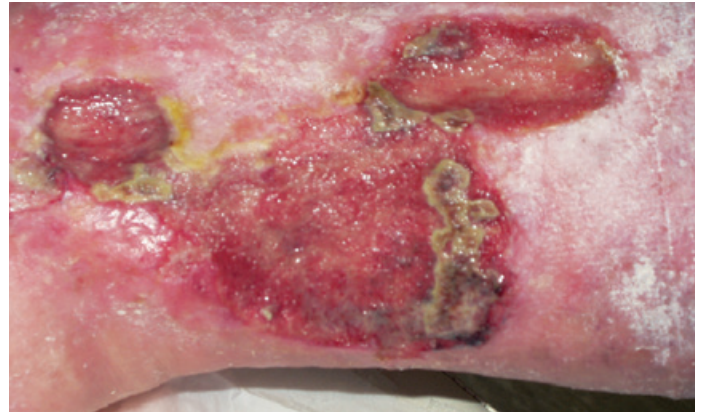21.08.2006  
Complete healing of the malleolar wound. A paraffin-impregnated net was applied to the crural wound. Almost complete healing of the crural ulcer occurred within a month.



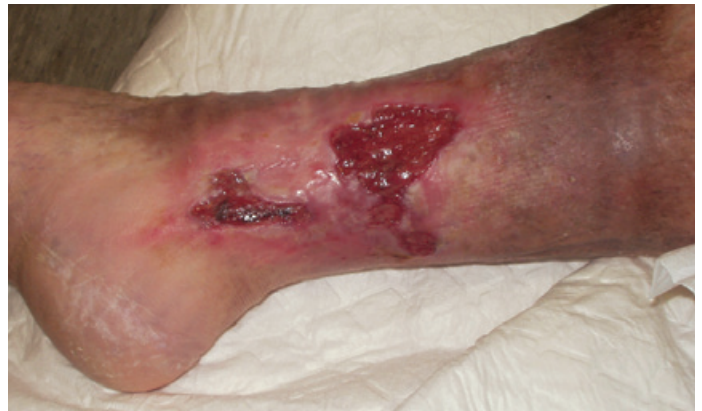10.08.2006  
The wound is clean. Epithelialisation has started 3 weeks later.  
The size of the wound has reduced by 50%.

# Venous Leg Ulcer

Responsible person for treatment	Ornella Forma
Institution	Centro di Vulnologia, Azienda Ospedaliera Macchi, Varese, Italy
Gender (female, male)	Male
Age of patient (year)	1932
Past medical history (PMH)	Venous insufficiency + Deep Venous Thrombosis
Medical treatment	Cardiovascular
Allergies	None
Wound diagnosis	Venous leg ulcer
Localisation of wound	Lower third, medial aspect of right leg
Age of wound	3 years
Previous treatment of wound	Iruxol® - Sofargen® - cleansing with Amuchina®
Reason for treatment change	Enrolled in wound care centre
Dressing change frequency	Every 3 days
Other products used	Hydroalginate - Collagen + COR
Outcome (final comment)	Optimal combination - Prontosan® Wound Irrigation Solution + dressing + elastic compression

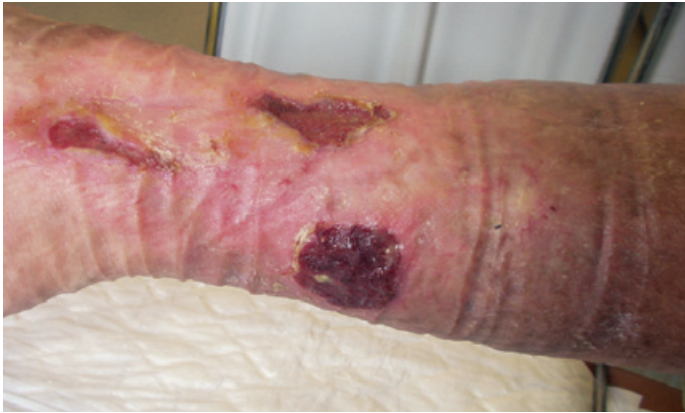

16.02.2006  
Painful ulcer with sloughy wound surface.

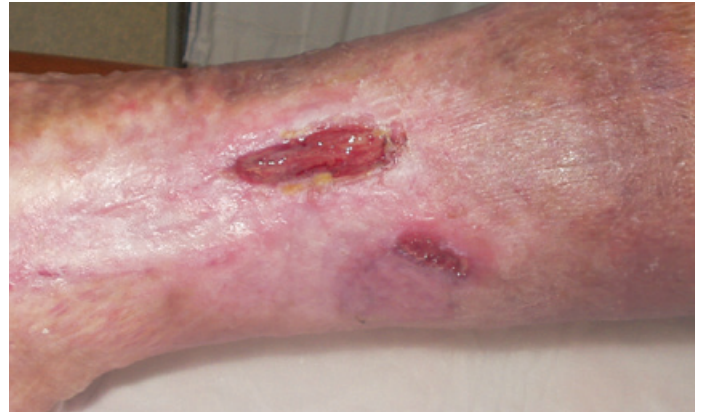

28.03.2006  
Good response. Removal of fibrin and complete pain relief.

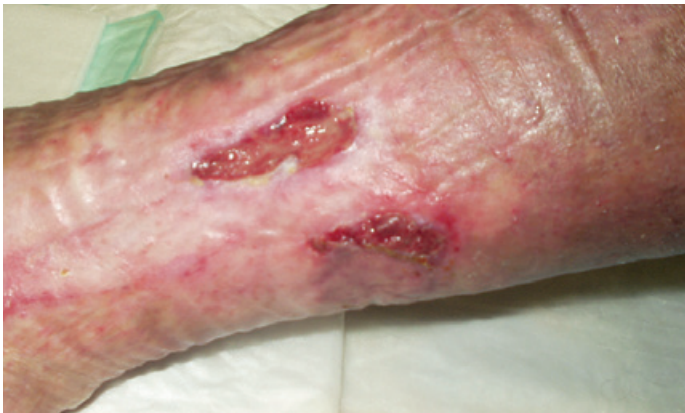



22.04.2006  
After admission for cardiac decompensation, new lesion from bandage – reduction of initial lesions.



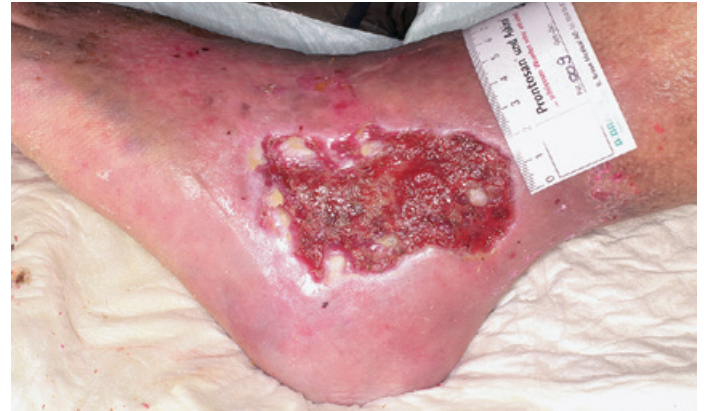22.05.2006  
Optimal response to treatment.



02.05.2006  
Complete closure of lower ulcer and remarkable reduction of the remaining two – change to collagen and COR dressing.

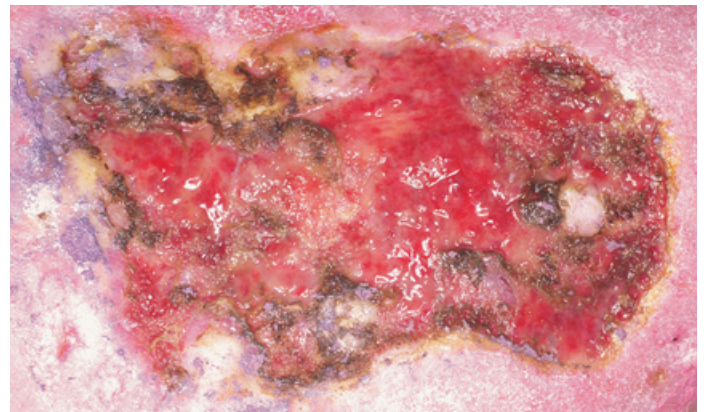
# Venous Leg Ulcer

Responsible person for treatment	–
Institution	University Hospital Zürich, Out Patient Clinics, Dermatology (once weekly), nursing home «Chlosterli», Unterägeri, Switzerland
Gender (female, male)	Male
Age of patient (year)	1934
Past medical history (PMH)	Chronic venous insufficiency
Medical treatment	Antibiotic treatment from 13. 04. 06 to 23. 04. 06
Allergies	Iodine allergy
Wound diagnosis	Ulcus cruris
Localisation of wound	Left lower leg
Age of wound	November 2004
Previous treatment of wound	Silvercel®, Carboflex®
Reason for treatment change	No progress in wound healing. Infected and odorous wound
Dressing change frequency	–
Other products used	Wound moistening and cleansing with Prontosan® Wound Irrigation Solution for 15 minutes, room temperature, Askina® Calgitrol Ag, Sorbion®, Excipial® U Lipolotio



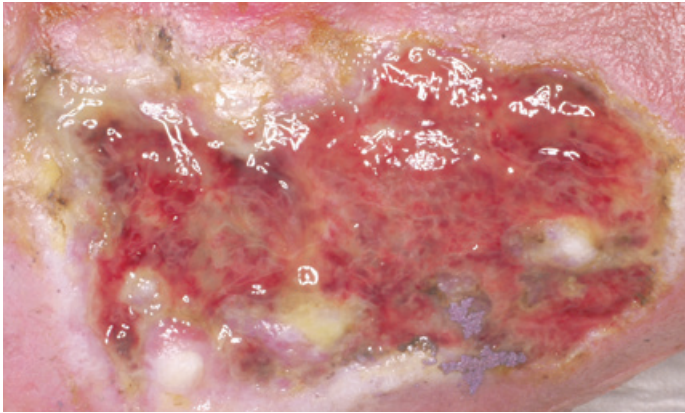
26.04.2006

Initial presentation: before cleansing and moistening of the wound

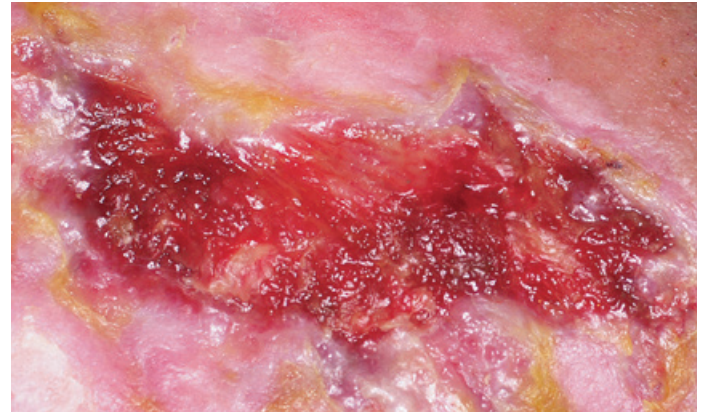


26.04.2006

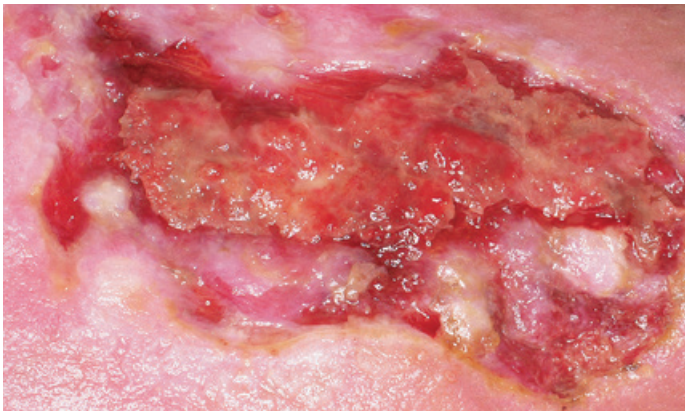
Initial presentation: before cleansing and moistening of the wound



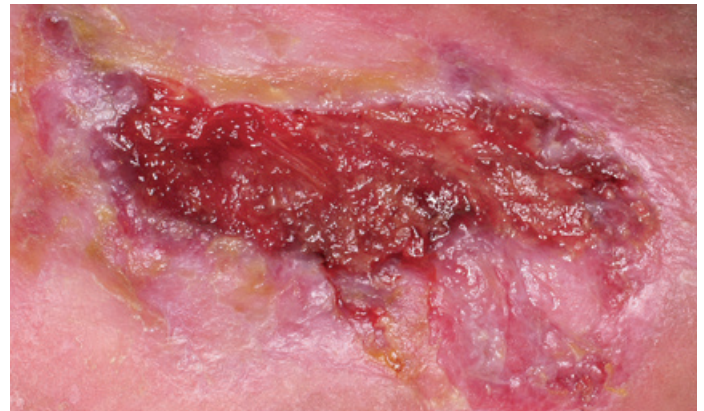
30.04.2006  
Before cleansing and moistening of the wound



26.05.2006  
After cleansing and moistening of the wound.  
Surface 808 mm<sup>2</sup>. F: 10 %. G: 90 %. N: 0 %



10.05.2006  
After cleansing and moistening of the wound.  
Surface 1193 mm<sup>2</sup>. F: 39 %. G: 81 %. N: 0 %

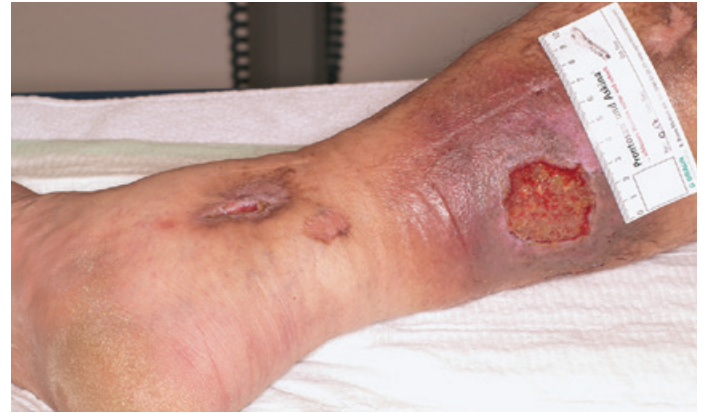

07.06.2006  
After cleansing and moistening of the wound.  
Surface 619 mm<sup>2</sup>. F: 2 %. G: 98 %. N: 0 %

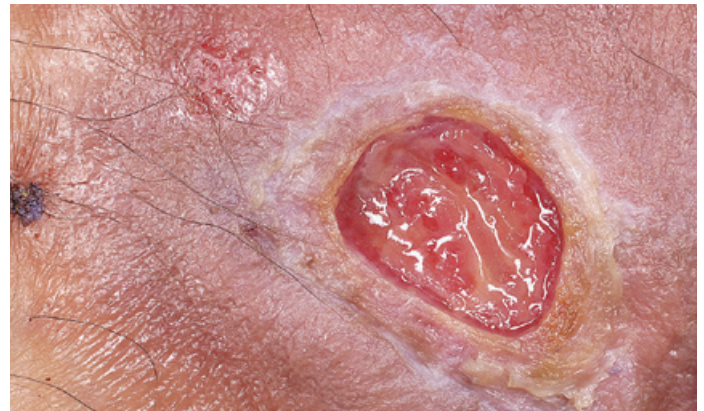


# Venous Leg Ulcer

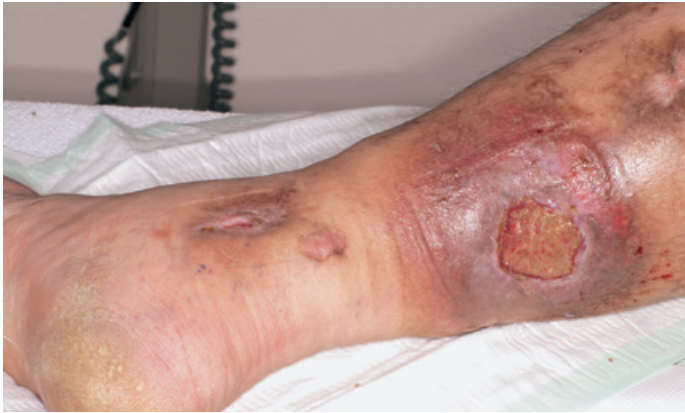Responsible person for treatment	–
Institution	Kantonsspital Aarau, Angiology, Switzerland
Gender (female, male)	Male
Age of patient (year)	1968
Past medical history (PMH)	Deep vein thrombosis, right leg, drug abuse, varicose vein operation, chronic venous insufficiency
Medical treatment	None
Allergies	None
Wound diagnosis	Ulcus cruris venosum
Localisation of wound	3 wound sites right leg
Age of wound	3 years
Previous treatment of wound	Flammazine®
Reason for treatment change	No progress in wound healing, wound coated with fibrin layer
Dressing change frequency	–
Other products used	Wound moistening and cleansing with Prontosan® Wound Irrigation Solution for 15 minutes, room temperature, Askina® Gel since 14.08.2006, Askina® Calgitrol Ag



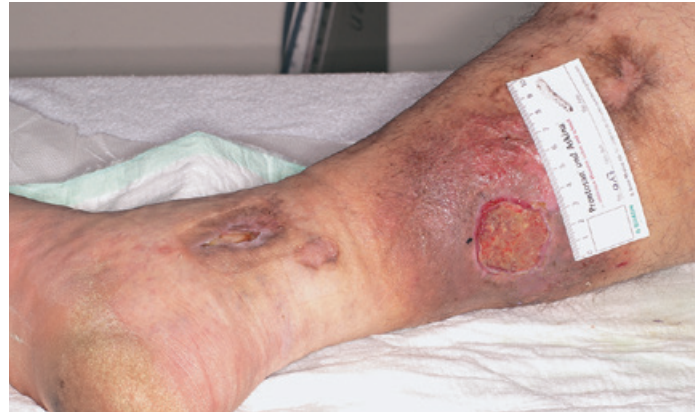10.07.2006  
After cleansing and moistening of the wound.



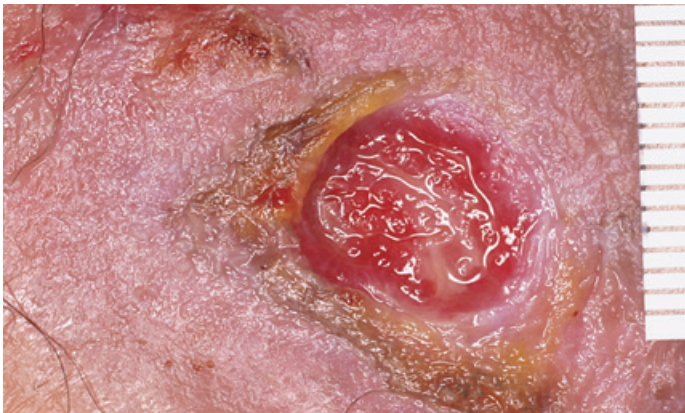
10.07.2006  
After cleansing and moistening of the wound.  
Surface 91 mm<sup>3</sup>. F: 69 %. G: 31 %. N: 0 %



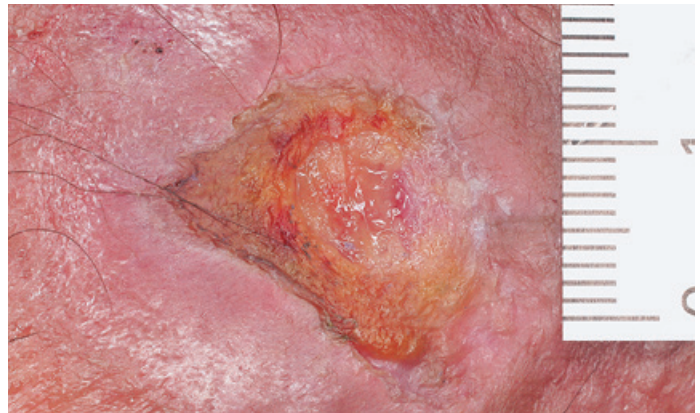17.07.2006  
After cleansing and moistening of the wound.



24.07.2006  
After cleansing and moistening of the wound.



17.07.2006  
After cleansing and moistening of the wound.  
Surface 36 mm<sup>2</sup>. F: 61 %. G: 39 %. N: 0 %

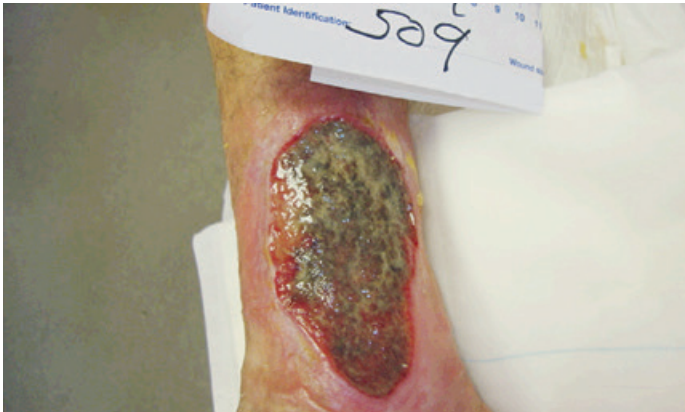

24.07.2006  
After cleansing and moistening of the wound.  
No further measurement possible.

# Venous Leg Ulcer

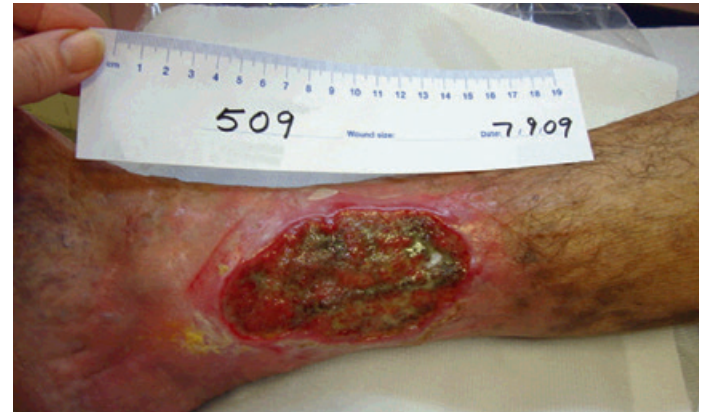Responsible person for treatment	Liz Ovens, BSc, RN, DN, Clinical Service Lead Tissue Viability
Institution	Hillingdon Community Health Hillingdon NHS, Complex Wound Clinic (CWC, London, United Kingdom)
Gender (female, male)	Female
Age of patient (year)	1926
Past medical history (PMH)	Chronic Lymphoid Leukaemia. There was no active treatment. Bilateral Knee Replacement, Aortic Stenosis, Bilateral stripping Varicose Veins, Recurrent Leg Ulcer, Hiatus Hernia
Allergies	–
Wound diagnosis	Within 3 days there was a noticeable difference in the wound bed. The raised shiny surface was no longer present. The pain score had reduced to 3 out of 10 and four layer bandaging was commenced and tolerated and frequency of dressings was reduced to twice weekly.
Localisation of wound	Left lateral Venous Leg Ulcer (VLU)
Age of wound	Six months
Previous treatment of wound	Multiple courses of broad spectrum antibiotics. Topical antiseptic hydrofibre dressing, support bandaging toe to knee. Required daily dressings to manage exudate and strike through.
Reason for treatment change	Several previous courses of antibiotics had proved unsuccessful and the wound swab demonstrated no bacterial growth. She had a high pain score of 8 out of 10 and was unable to tolerate high compression therapy and taking Co-Dydramol four times daily.
Dressing change frequency	Commenced dressings three times weekly <ul style="list-style-type: none"> <li>■ Irrigating then soaking wound with Prontosan® Wound Irrigation Solution for 10 minutes.</li> <li>■ Applying Prontosan® Gel to wound bed.</li> <li>■ Applying Hydrofibre Ag and multi-layer Hydrofibre to absorb exudate.</li> <li>■ Continued support bandaging as before.</li> </ul>
Other products used	Co-Dydramol up to 8 daily, Diazepam 5 mgs OD, Omeprazole 20 mgs OD, Calcium Carbonate and Calciferol 1.5 g and 10 mcg
Outcome (final comment)	It appears that the combination of the antimicrobial effect of PHMB and the cleansing effect of Betaine disturbed the biofilm layers thus reducing bioburden. The cost of wound management was reduced with only weekly visits by the District Nurses being required compared to daily visits prior to intervention, and through reduced use of antibiotics.





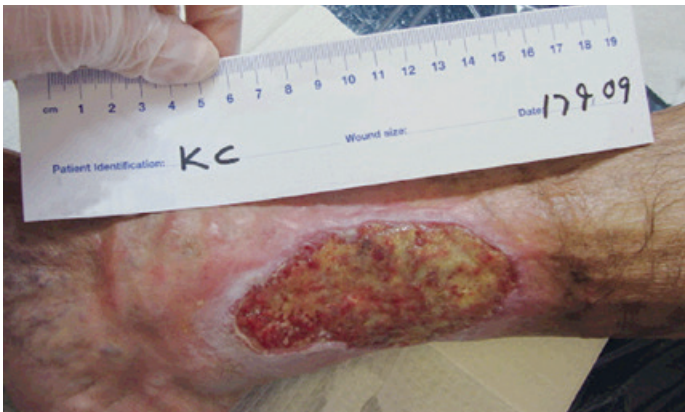03.09.2009

The wound to the left lateral aspect measured 38 sq cms with 100% slough and covered in a glassy, sticky structure that lay proud of the wound bed and had green malodorous exudate



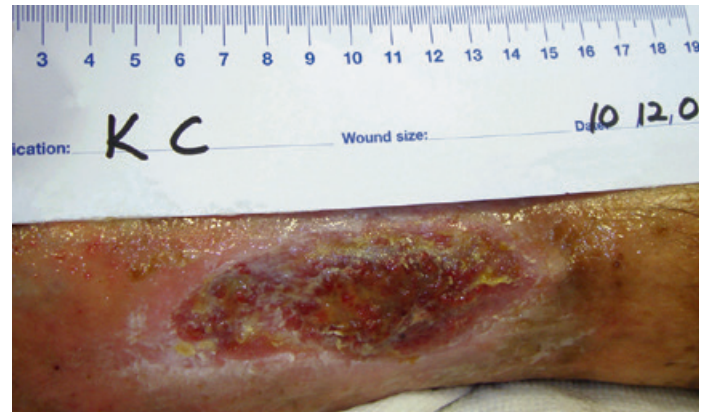07.09.2009

Evidence of approximately 25% granulation tissue and less peri-ulcer inflammation.



17.09.2009

Two weeks after initiation of treatment regime, the wound bed had reduced in size to 34 cms sq and had 50% granulation tissue



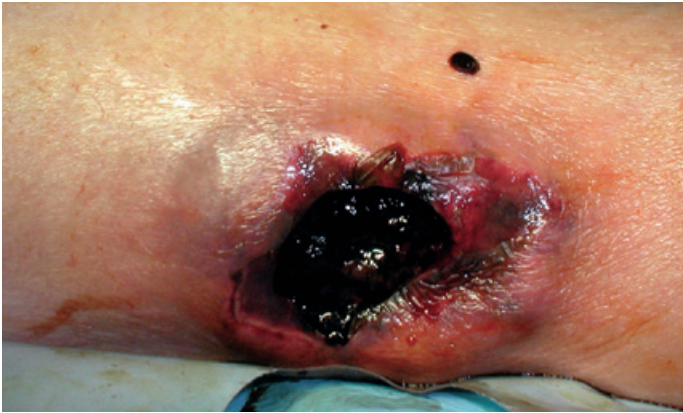10.12.2009

12 weeks later the wound measured 16 cms sq with 98% granulation and required weekly dressings.

# Traumatic Wound

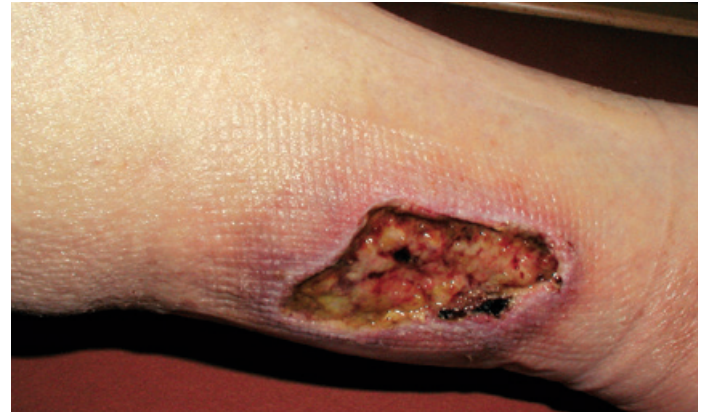Responsible person for treatment	Eric Roovers
Institution	ZNA Middelheim, Lindendreef 1, 2020 Antwerp, Belgium
Gender (female, male)	Female
Age of patient (year)	1914
Past medical history (PMH)	Traumatic wound
Medical treatment	–
Allergies	–
Wound diagnosis	Haematoma with necrosis
Localisation of wound	Right lower leg
Age of wound	14 days
Previous treatment of wound	None
Reason for treatment change	–
Dressing change frequency	Twice daily
Other products used	Isobetadine® Dermicum, wick gauze, Purilon® Hydrogel





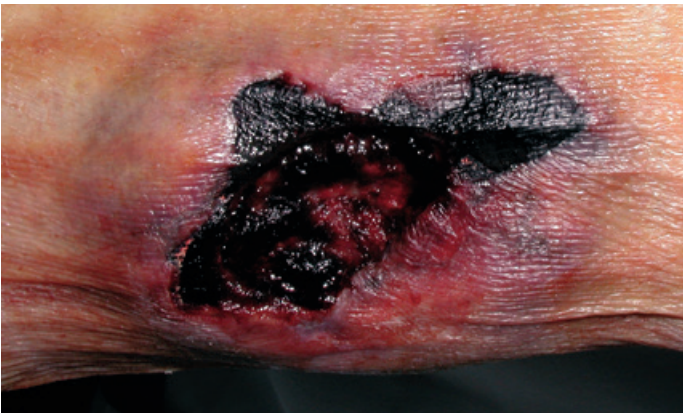11.10.2006

Haematoma (traumatic) 14 days prior to patient's admission to RVT.  
Necrosis of the skin. Treatment: remove necrosis, rinse old blood and necrosis,  
Prontosan® Wound Irrigation Solution twice daily, Isobetadine® wick.



23.10.2006

Continue same treatment + hydrogel application to promote granulation to plan  
grafting.

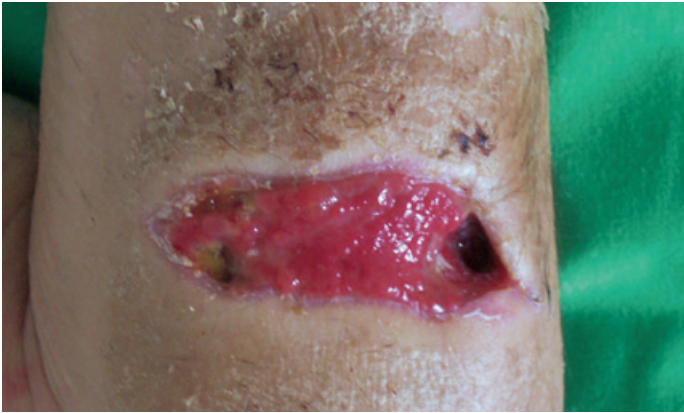


12.10.2006

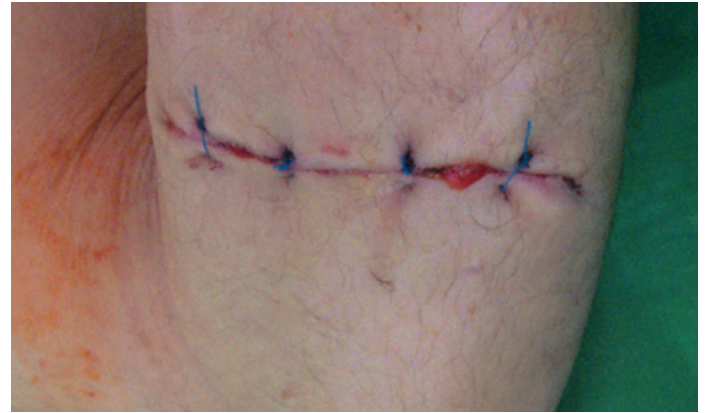Rinse with physiological solution, application of Prontosan® Wound Irrigation  
Solution for 15 minutes, Isobetadine® wick.

# Traumatic Wound

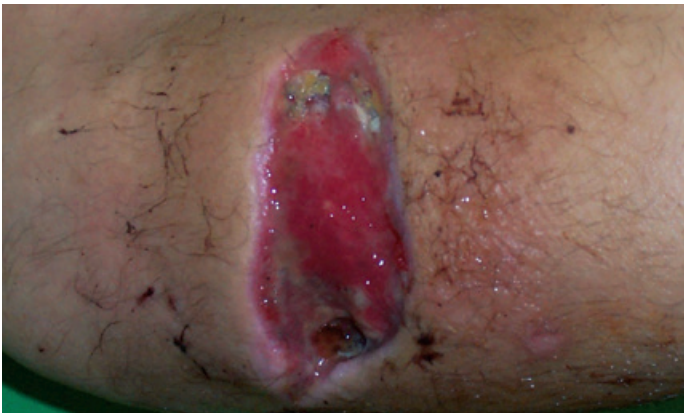Responsible person for treatment	Dr. M. J.
Institution	Szeged, Hungary
Gender (female, male)	Male
Age of patient (year)	1963
Past medical history (PMH)	A cutting disc (flex disc) injured his left forearm, producing an open wound.
Medical treatment	Antibiotics (Augmentin®, Klion®)
Allergies	None
Wound diagnosis	Sanguineous, purulent discharge, pain
Localisation of wound	Left forearm
Age of wound	10 days
Previous treatment of wound	Braunol®
Reason for treatment change	Stagnating wound
Dressing change frequency	Once a day
Other products used	No other product was used
Outcome (final comment)	The accelerated rate of healing and lack of infection allowed wound closure.



29.06.2006  
Hypergranulated and painful wound.



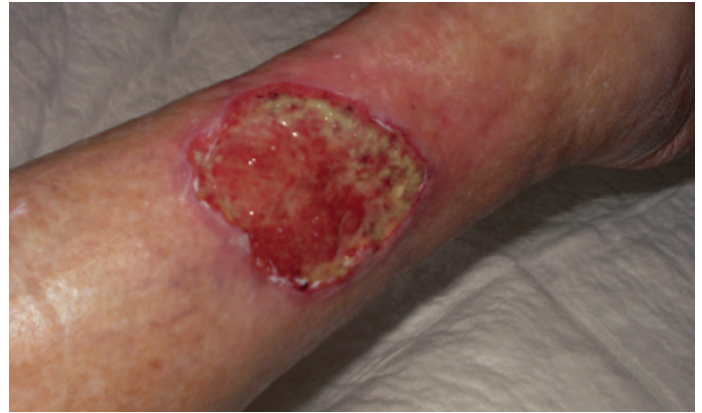17.07.2006  
After 15 days of treatment, the wound cleaned up and wound closure could be performed.



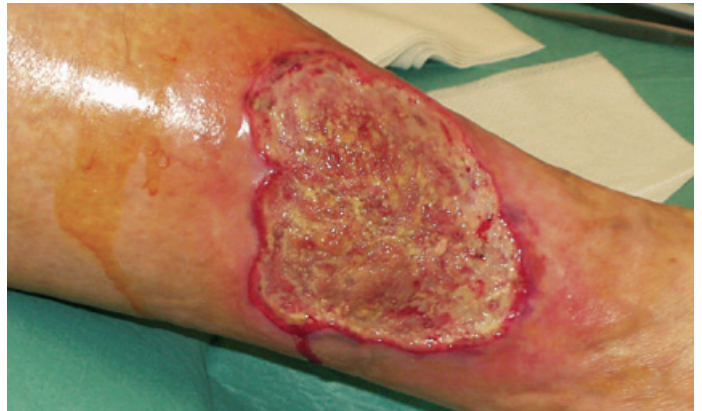07.07.2006  
After 8 days of granulation, both depth and size of the wound reduced.

# Traumatic Wound

Responsible person for treatment	Ornella Forma
Institution	Centro di Vulnologia, Azienda Ospedaliera Macchi, Varese, Italy
Gender (female, male)	Female
Age of patient (year)	1974
Past medical history (PMH)	Vasculitis
Medical treatment	Mogador®, Imesulide® s.o.
Allergies	None
Wound diagnosis	Post-traumatic
Localisation of wound	Middle third, lateral aspect of right leg
Age of wound	1 year
Previous treatment of wound	Silver sulfadiazine, collagenase with CAF
Reason for treatment change	Cytotoxicity
Dressing change frequency	3 times a week
Other products used	Hydroalginate with silver ions
Outcome (final comment)	Good response adding Prontosan® Wound Irrigation Solution to antibacterial dressing

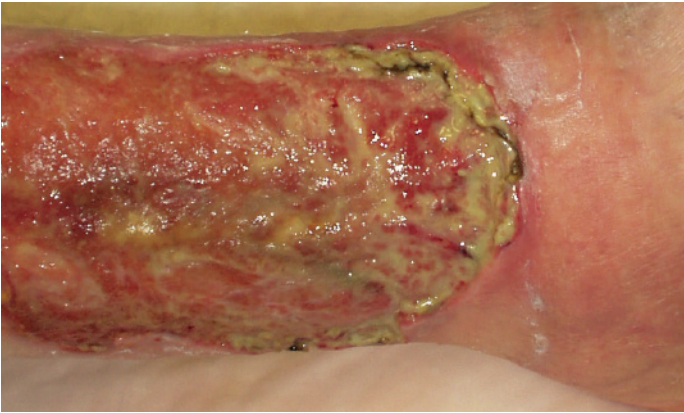

01.03.2006  
Severe pain, reddened margins with oedema.

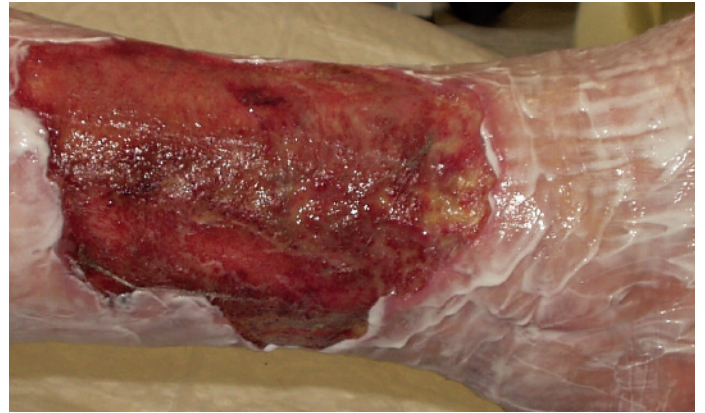

25.03.2006  
Further increase in wound size.

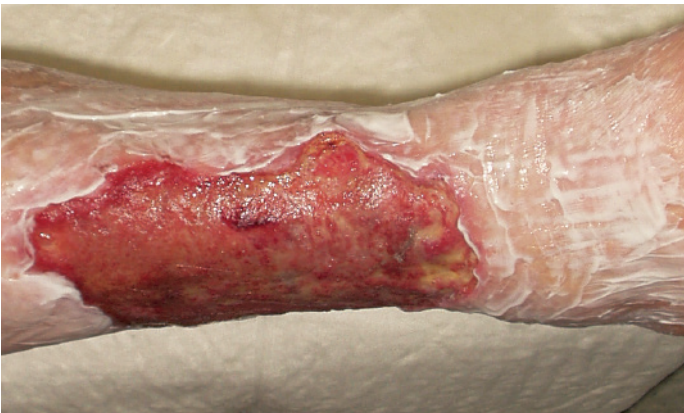



20.04.2006  
Starting of using Prontosan® Wound Irrigation Solution. Increasing size of the ulcer. The pain symptoms persisted. Systemic antibiotic for 15 days. Prontosan® Wound Irrigation Solution + CMC with silver ions.



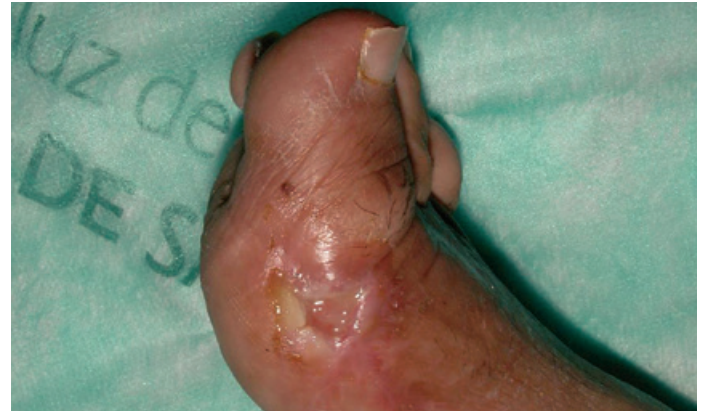15.05.2006  
Well-granulating tissue with good response to treatment regimen.



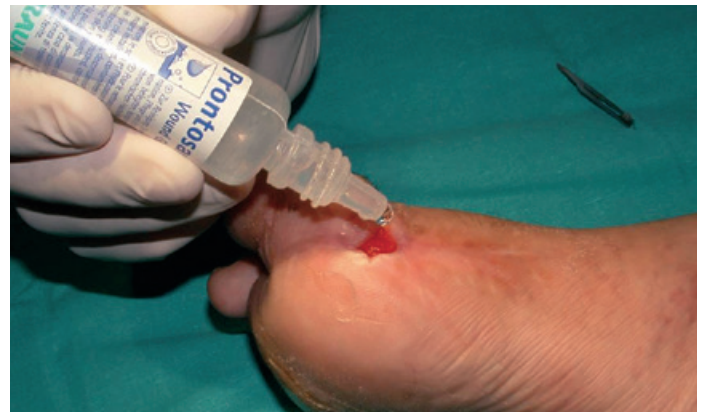05.05.2006  
Immediate pain relief with no signs of infection.

# Traumatic Wound

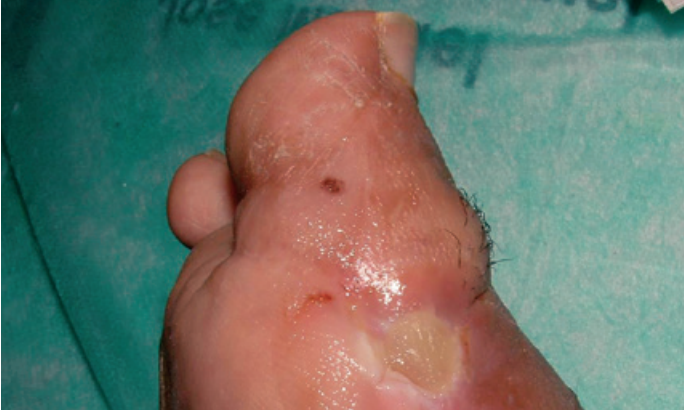Responsible person for treatment	–
Institution	Hosp. General Santa María del Puerto, Cádiz, Spain
Gender (female, male)	Male
Age of patient (year)	1968
Past medical history (PMH)	Motorbike accident: knee abrasion
Medical treatment	–
Allergies	–
Wound diagnosis	Fibrin coated wound, exudation
Localisation of wound	Right knee
Age of wound	Acute wound
Previous treatment of wound	Dry treatment: Povidone-Iodine gauze
Reason for treatment change	Wound infection
Dressing change frequency	Every two days
Other products used	Prontosan® Wound Gel, Askina® Calgitrol Ag, Askina® Transorbent, Askina® Sorb
Outcome (final comment)	Complete healing of the wound after 62 days



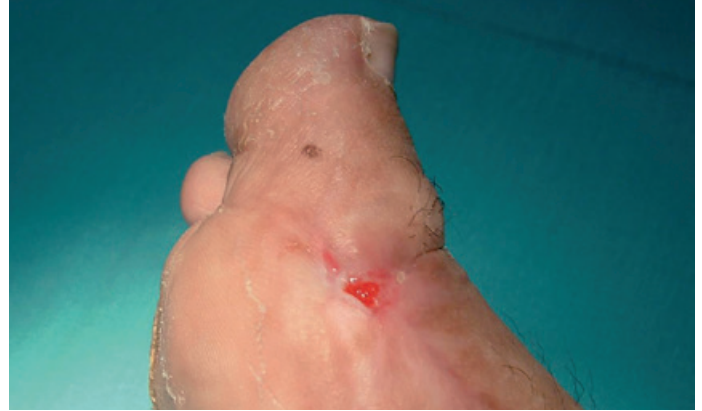14.11.2005  
Fibrin coated and exudative wound.



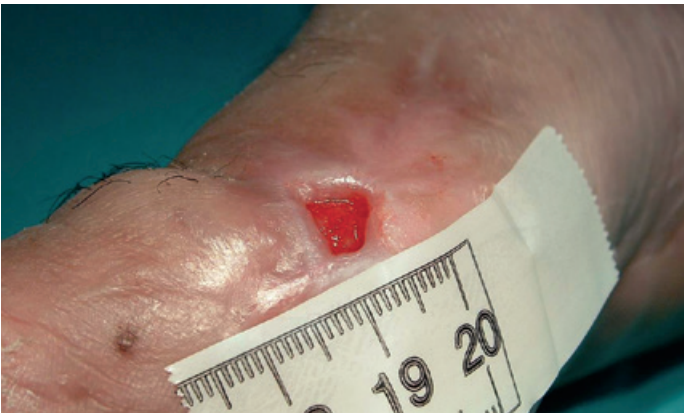14.11.2005  
Wound bed preparation: after Prontosan® Wound Irrigation Solution and surgical debridement, application of Prontosan® Gel and foam dressing (Askina® Transorbent).



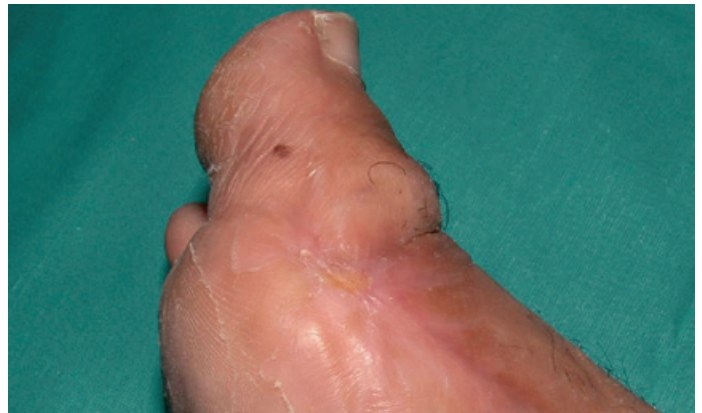21.11.2005  
Wound appearance after two treatments, reduction in wound size. Fibrin coating will disappear after Prontosan® Wound Irrigation Solution and surgical debridement.



01.12.2005  
Wound becomes almost healed.



24.11.2005  
Wound aspect: significant reduction in wound size and good granulation tissue.

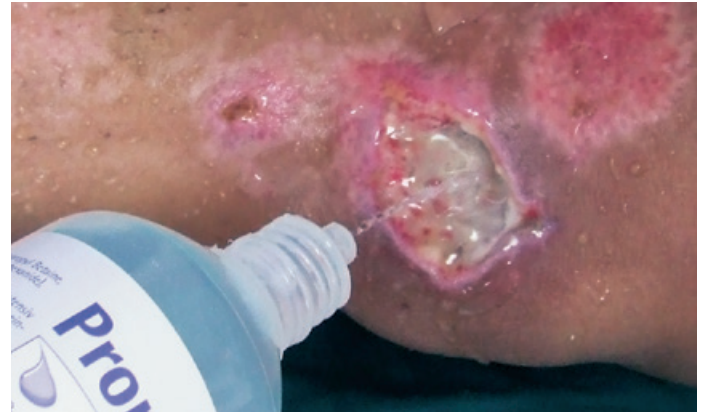

12.12.2005  
Complete epithelialisation of the wound.



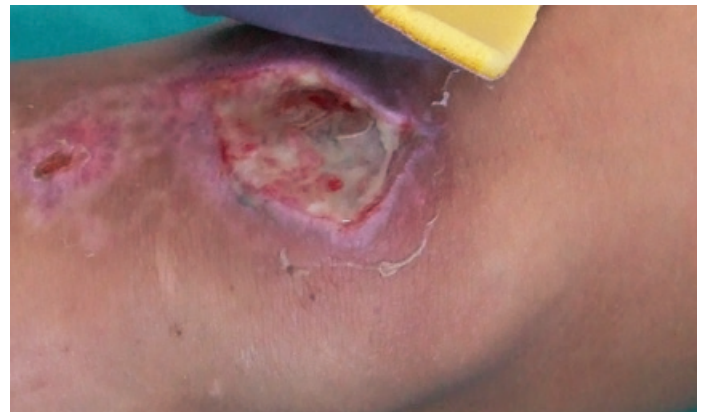# Traumatic Wound

Responsible person for treatment	Manuel Castañeda
Institution	Hosp. General Santa María del Puerto, Cádiz, Spain
Gender (female, male)	Male
Age of patient (year)	1968
Past medical history (PMH)	Motorbike accident
Medical treatment	–
Allergies	–
Wound diagnosis	Important tissue loss. Infected wound
Localisation of wound	Right knee
Age of wound	–
Previous treatment of wound	Dry treatment: gauze, Povidone-Iodine
Reason for treatment change	No improvement of the wound
Dressing change frequency	Every two days
Other products used	Prontosan® Gel, Askina® Transorbent, Askina® Sorb
Outcome (final comment)	Complete healing of the wound after 62 days



07.04.2006

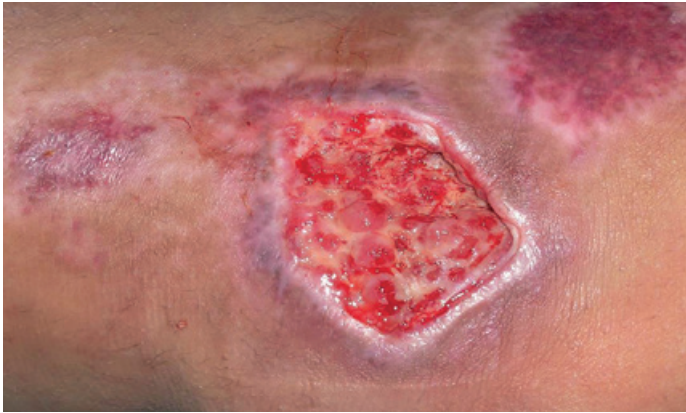Deep wound with important tissue loss. Infected wound. Wound treatment: wound cleansing with Prontosan® Wound Irrigation Solution and wound infection treatment with Prontosan® Wound Gel + Askina® Calgitrol Ag (changes every 2 days)



14.04.2006

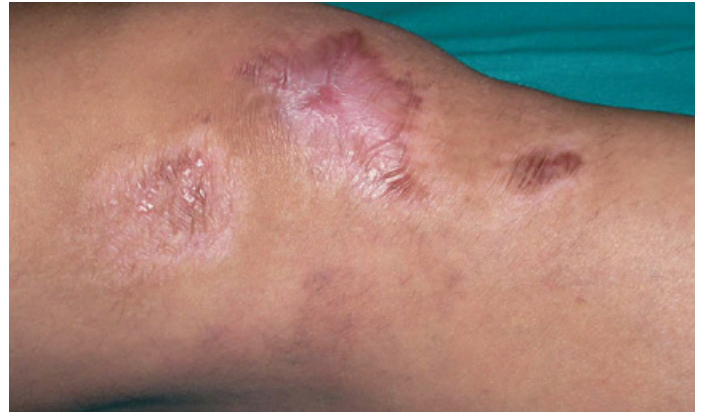Antimicrobial treatment is maintained during 2 weeks (no signs of infection).





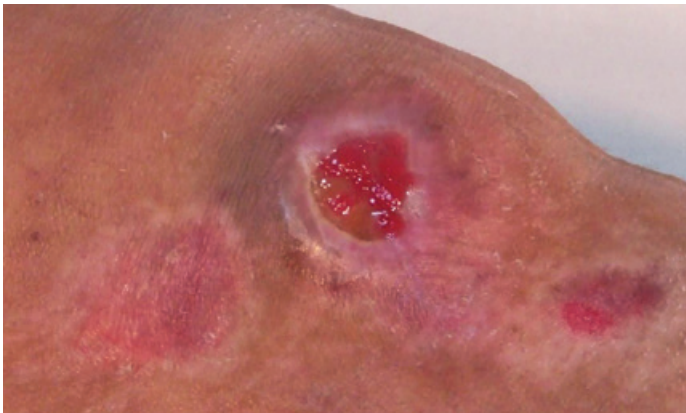
02.05.2006

Infection was under control, significant reduction of wound size with good granulation and epithelialisation tissue. Wound treatment: Prontosan® Wound Irrigation Solution and Prontosan® Wound Gel + Askina® Transorbent



09.06.2006

Complete epithelialisation of the wound.

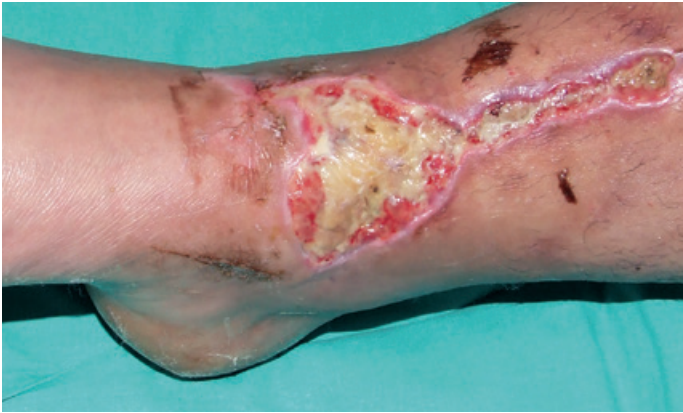

02.06.2006

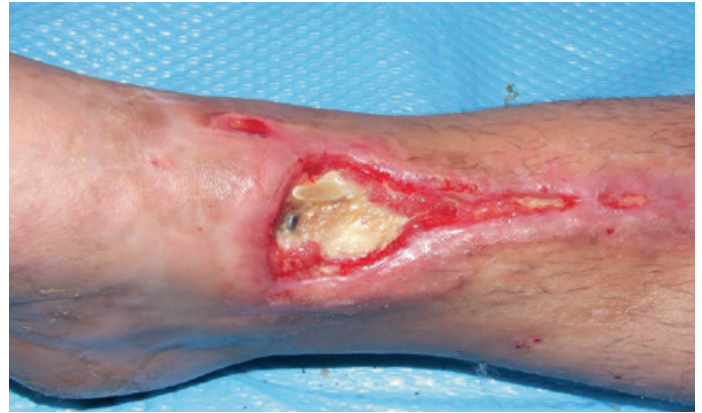One month later. Wound aspect: significant reduction of wound size and good granulation tissue. Same wound treatment.

# Traumatic Wound

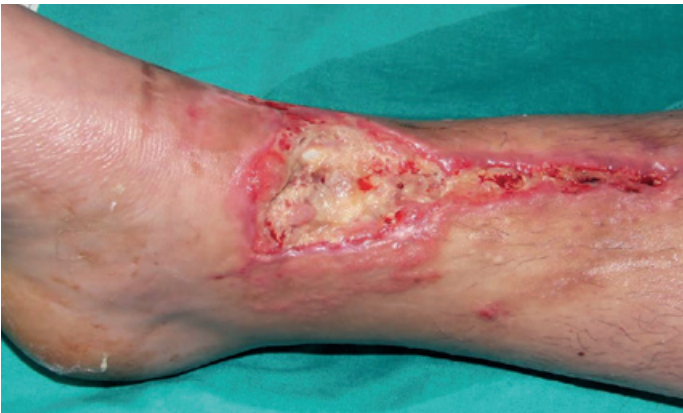Responsible person for treatment	Manuel Castañeda
Institution	Hosp. Universitario de Puerto Real, Cádiz, Spain
Gender (female, male)	Female
Age of patient (year)	1988
Past medical history (PMH)	Bull gored
Medical treatment	–
Allergies	–
Wound diagnosis	Tibia and fibula fracture
Localisation of wound	Right foot
Age of wound	2004
Previous treatment of wound	Many foot operations. Traditional wound treatment (gauze, ...)
Reason for treatment change	No improvement of the wound and wound infection
Dressing change frequency	Every 3–4 days
Other products used	Prontosan® Wound Gel, Askina® Transorbent
Outcome (final comment)	Wound improvement after 53 days



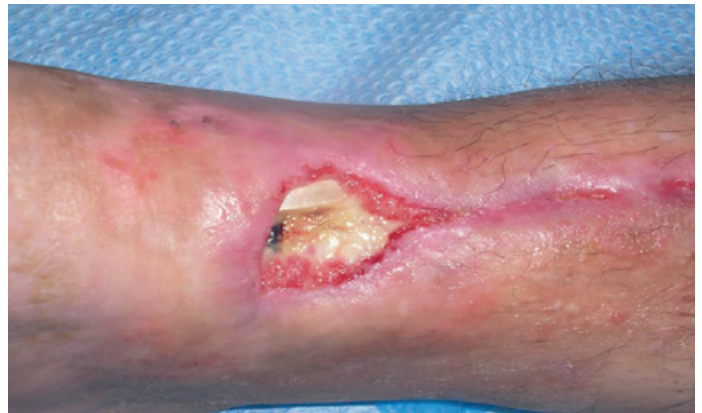01.06.2006  
Infected wound. Rinsing with Prontosan® Wound Irrigation Solution. Wound infection treatment with Prontosan® Wound Gel + Askina® Calgitrol Ag.



06.07.2006  
Infection was under control, significant reduction in wound size with good granulation and epithelialisation tissue. Wound treatment: Prontosan® Wound Irrigation Solution and Prontosan® Wound Gel + Askina® Transorbent



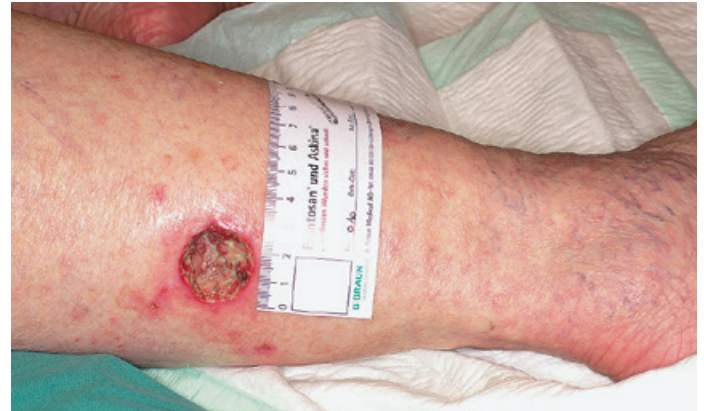15.06.2006  
Wound aspect after two weeks under same treatment. Wound cleansing and wound infection treatment.



24.07.2006  
Final evaluation: significant reduction in wound size and good granulation tissue.

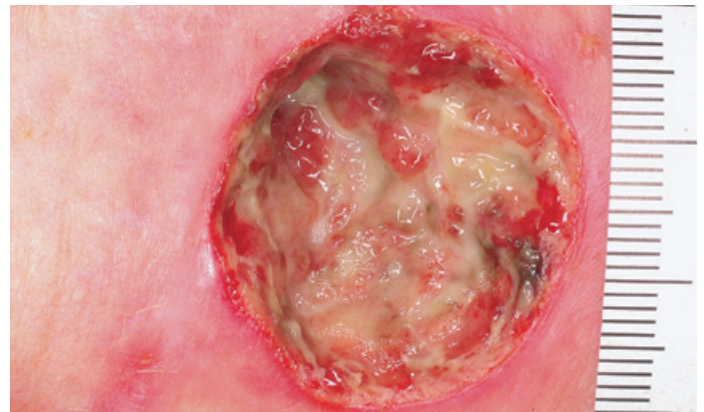# Traumatic Wound

Responsible person for treatment	–
Institution	University Hospital Zürich, Out Patient Clinics, Dermatology, Switzerland
Gender (female, male)	Female
Age of patient (year)	1924
Past medical history (PMH)	Not known
Medical treatment	None
Allergies	None
Wound diagnosis	Wound break down after fall
Localisation of wound	Left lower leg, distally
Age of wound	4 weeks
Previous treatment of wound	Aquacel® Ag
Reason for treatment change	No progress in wound healing. Infected wound
Dressing change frequency	–
Other products used	Wound moistening and cleansing with Prontosan® Wound Irrigation Solution for 15 minutes, room temperature, Askina® Calgitrol Ag multi layered



02.05.2006

Initial presentation: before cleansing and moistening of the wound

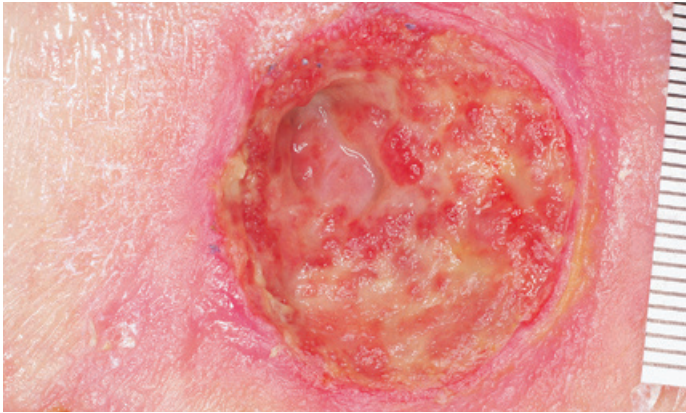

02.05.2006

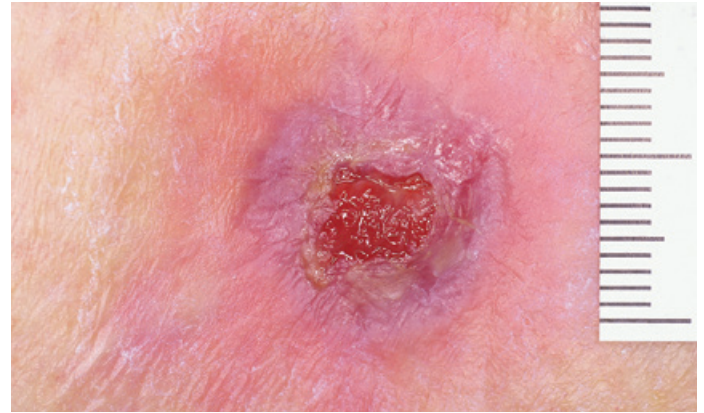
After cleansing and moistening of the wound.

Surface 464 mm<sup>2</sup>. F: 71 %. G: 28 %. N: 1 %

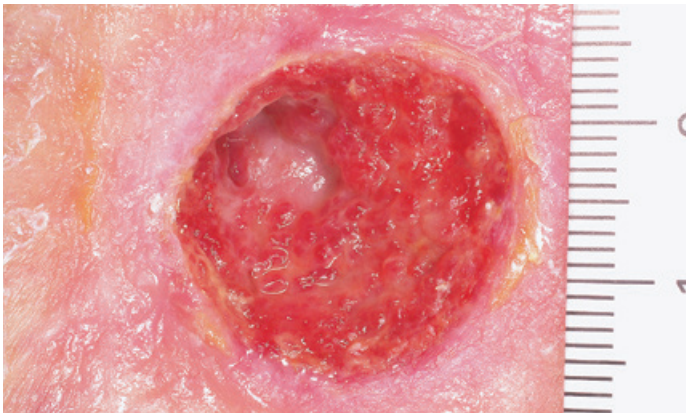




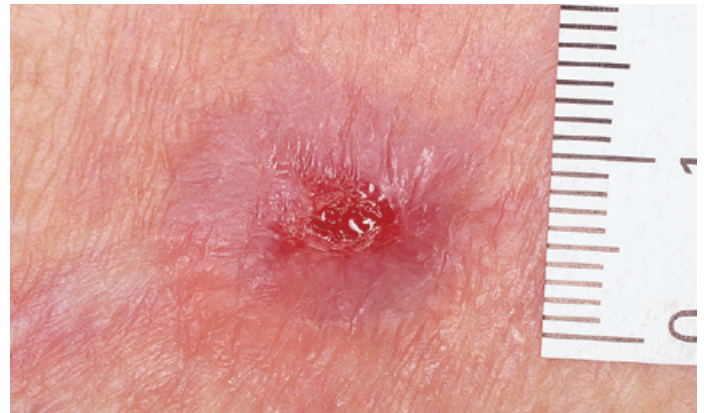
08.05.2006  
After cleansing and moistening of the wound.  
Surface 451 mm<sup>2</sup>. F: 66 %. G: 34 %. N: 0 %



01.06.2006  
After cleansing and moistening of the wound.  
Surface 107 mm<sup>2</sup>. F: 38 %. G: 62 %. N: 0 %



15.05.2006  
After cleansing and moistening of the wound.  
Surface 276 mm<sup>2</sup>. F: 28 %. G: 72 %. N: 0 %

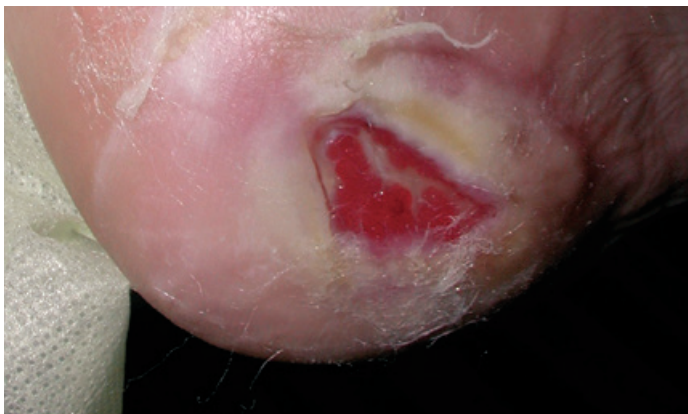

06.07.2006  
After cleansing and moistening of the wound. No further measurement possible

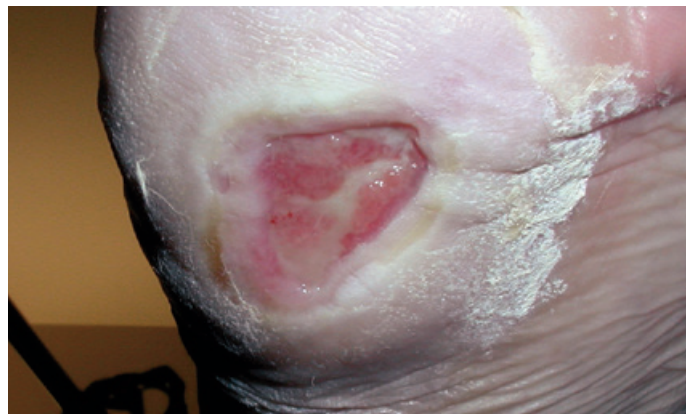# Pressure Ulcer

Responsible person for treatment	Eric Roovers
Institution	ZNA Middelheim, Lindendreef 1, 2020 Antwerp, Belgium
Gender (female, male)	Female
Age of patient (year)	1927
Past medical history (PMH)	Decubitus
Medical treatment	Diabetic
Allergies	–
Wound diagnosis	Yellow, MRSA positive
Localisation of wound	Left heel
Age of wound	Minimum 5 months
Previous treatment of wound	Various, last SeaSorb® (alginate)
Reason for treatment change	MRSA
Dressing change frequency	Once daily
Other products used	Cavilon® spray, SeaSorb®

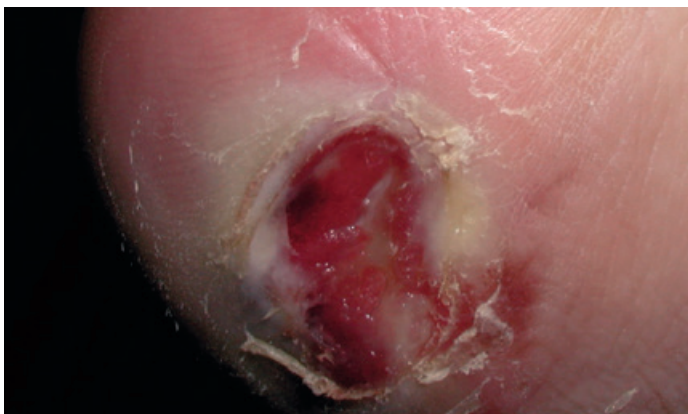




27.09.2006  
Start of Prontosan® Wound Irrigation Solution treatment.



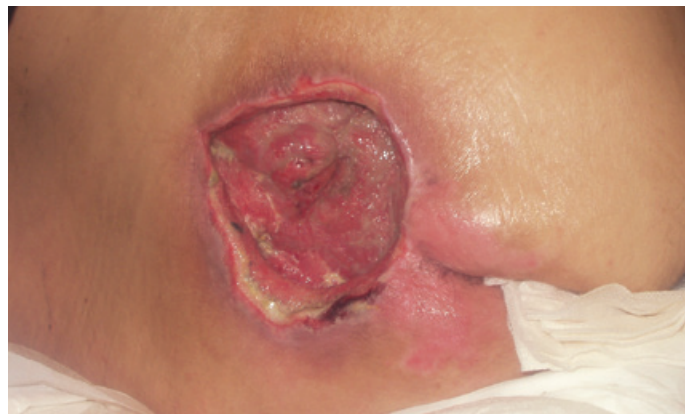18.10.2006  
Favourable evolution, further treatment with Prontosan® Wound Irrigation Solution.



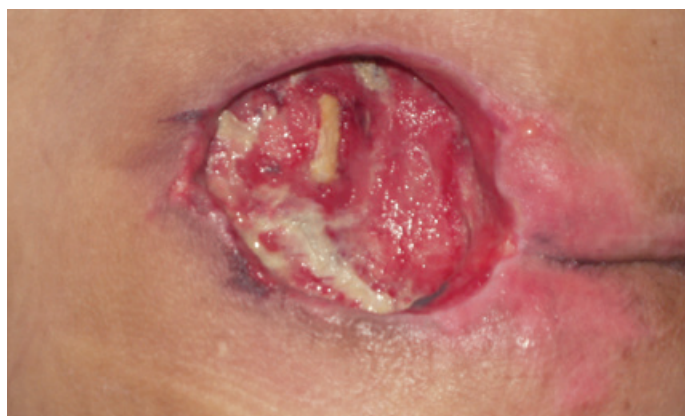11.10.2006  
Favourable evolution, further treatment with Prontosan® Wound Irrigation Solution.

# Pressure Ulcer

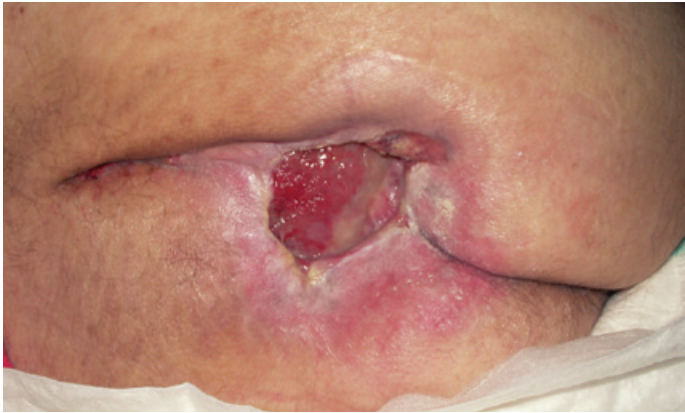Responsible person for treatment	Ornella Forma
Institution	Centro di Vulnologia, Azienda Ospedaliera Macchi, Varese, Italy
Gender (female, male)	Male
Age of patient (year)	1947
Past medical history (PMH)	Sacral decubitus ulcer
Medical treatment	None
Allergies	None
Wound diagnosis	Stage IV
Localisation of wound	Sacral
Age of wound	6 months
Previous treatment of wound	Iodoform® gauze
Reason for treatment change	Inadequate
Dressing change frequency	Daily
Other products used	In succession, antibacterials, absorbents
Outcome (final comment)	The treated lesion improved over the course of few weeks



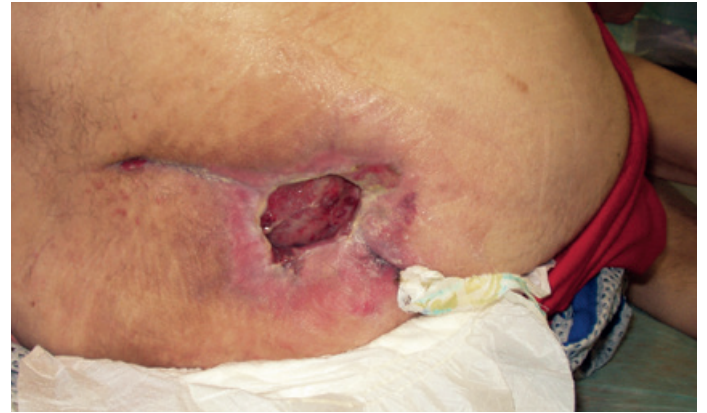10.01.2006  
Fibrinous wound surface, heavy exudation.



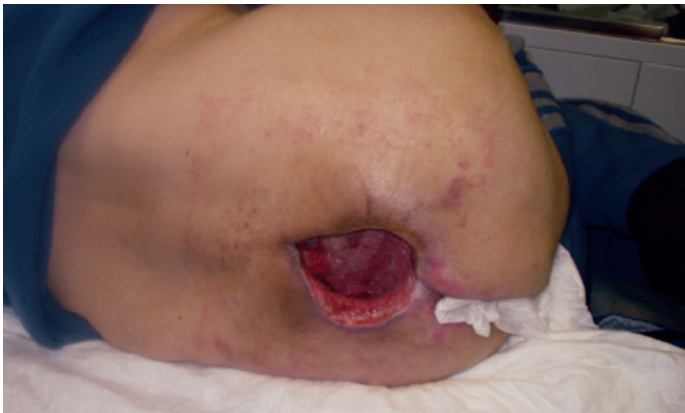09.02.2006  
Good cleansing of wound surface with reduction of exudate.



21.03.2006  
Remarkable reduction of wound size using V.A.C. system.



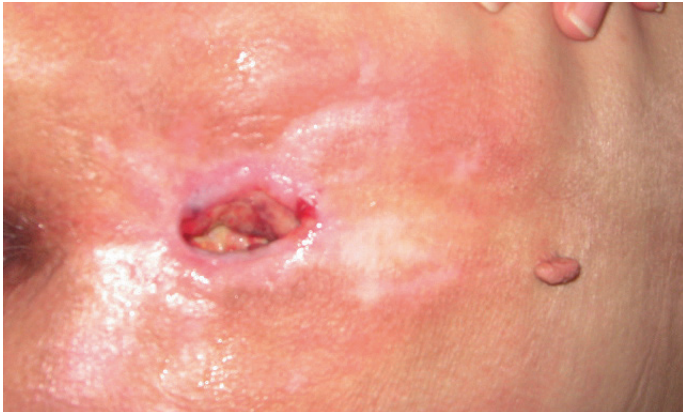
14.04.2006  
Progress in wound healing with Prontosan® Wound Irrigation Solution and hydroalginates.



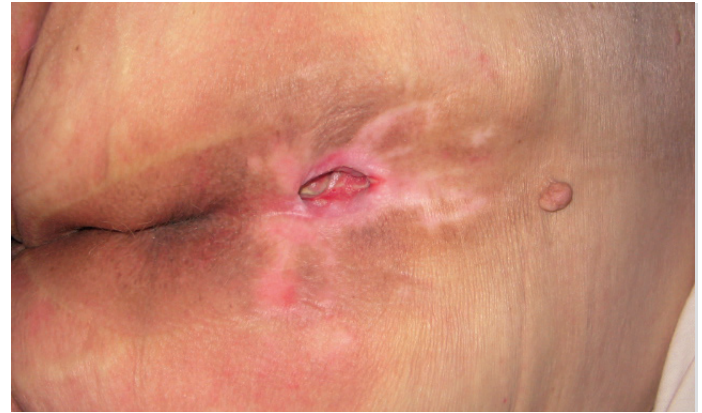31.03.2006  
After one week of reusing Prontosan® Wound Irrigation Solution.

# Pressure Ulcer

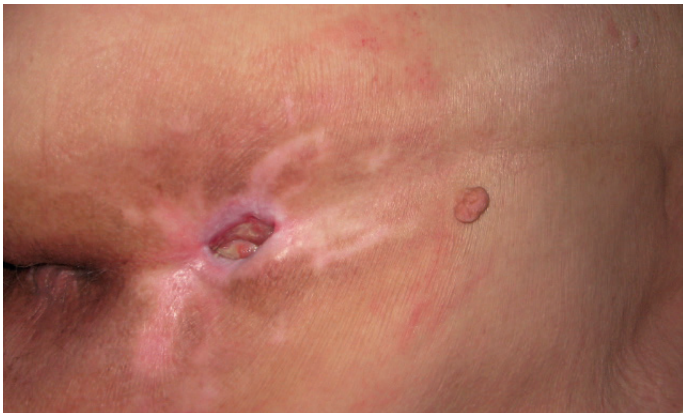Responsible person for treatment	M. Jansson
Institution	Älvuddens sjukhem, Gagnef kommun, Sweden
Gender (female, male)	Female
Age of patient (year)	1909
Past medical history (PMH)	–
Medical treatment	None
Allergies	None
Wound diagnosis	Exudating wound, evidence of moderate inflammation, pain
Localisation of wound	Sacrum
Age of wound	Wound break down June 12th, 2006
Previous treatment of wound	Purilon® Gel application
Reason for treatment change	Nothing happened with previous Purilon® treatment
Dressing change frequency	Every 3 days
Other products used	Prontosan® Wound Irrigation Solution and Prontosan® Wound Gel
Outcome (final comment)	So far the wound size has reduced and has become more shallow



10.10.2006: Prior to Prontosan® Wound Irrigation Solution treatment. Wound break down June 12th, 2006. Suspected growth of *Pseudomonas aeruginosa*. For that reason Ciprofloxacin was prescribed. Mechanical cleansing of the wound. Good nutritional status of the patient. The wound was relieved from pressure.



21.11.2006  
Further reduction of wound size. Disappearance of odour. Complete pain relief.

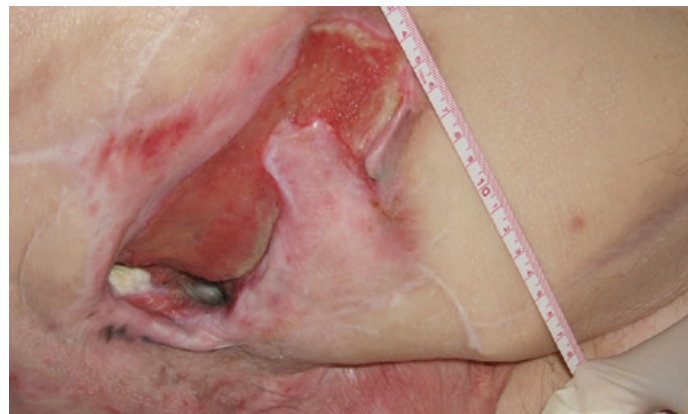

16.10.2006  
The wound was cleansed with Prontosan® Wound Irrigation Solution fast and effectively. The wound size has been reduced (both surface and depth).



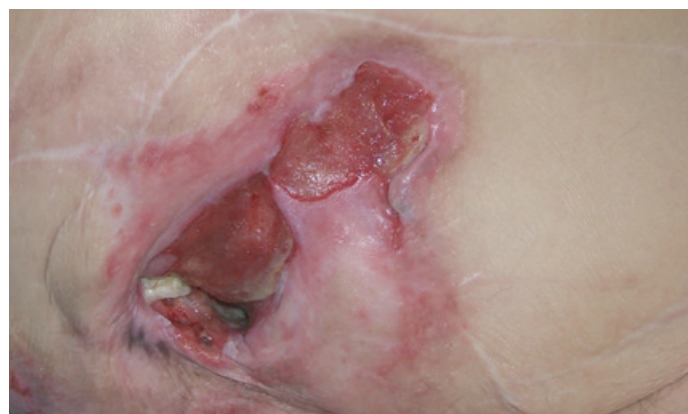# Pressure Ulcer

Responsible person for treatment	Ann Horrocks, Tissue Viability Nurse Specialist
Institution	South Somerset Primary Care Trust, United Kingdom
Gender (female, male)	Male
Age of patient (year)	1941
Past medical history (PMH)	Tetraplegia for 18 years, NIDD, chronic anaemia
Medical treatment	Antibiotics to treat infection
Wound diagnosis	Wounds necrotic, malodourous; signs of bleeding; infected
Localisation of wound	Large grade 4 pressure ulcer and smaller deep grade 4 ulcer
Age of wound	5 years
Previous treatment of wound	Surgery; V.A.C., numerous products, e.g.silver dressing. Cleansing with saline; 2 week episodes of Aquacel® and Aquacel® Ag; Mepilex®
Reason for treatment change	1 <sup>st</sup> February 2006, wound kept getting repeated infection
Dressing change frequency	Meplix® changed daily for the first 4 weeks then alternative days after reduction in size and depth of the wound
Other products used	Stop of saline and start of Prontosan® 10 minute soaks. All silver dressings stopped. Prontosan® Wound Gel applied as primary wound contact
Outcome (final comment)	Infection with Ps. aeruginosa. Silver dressings for 2 weeks. Reduction of odour and exudate, good haemostasis. No further antibiotics were required



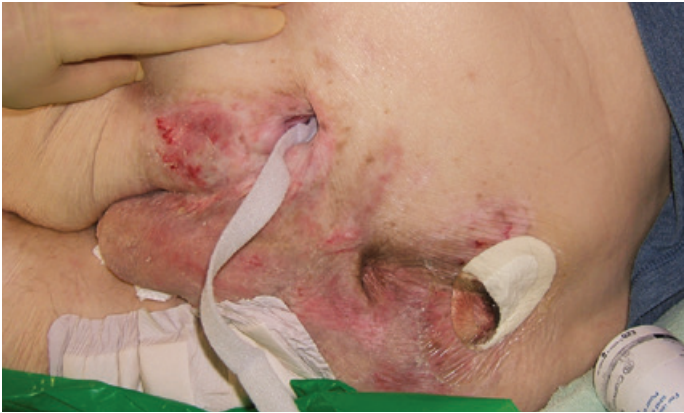12.04.2006

Ulcer 1: immediately after commencing Prontosan® treatment the small ulcer produced less exudate and dressing changes with an alginate rope were reduced to alternate days.

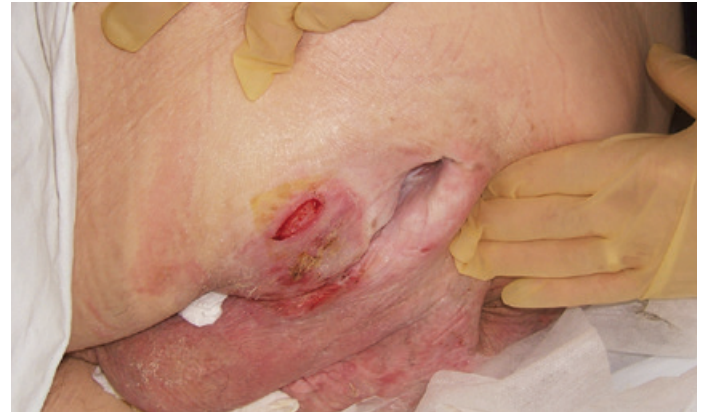

14.04.2006

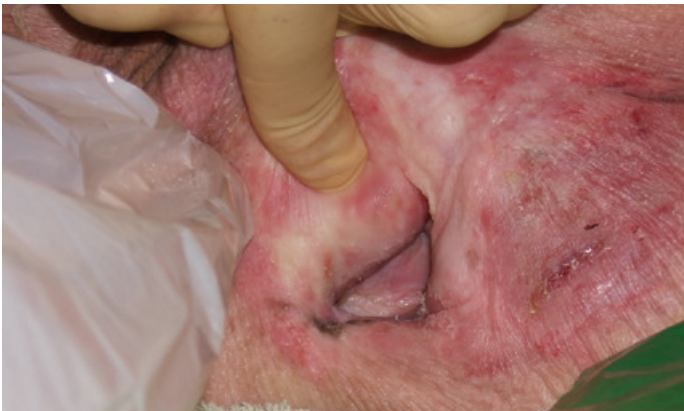Ulcer 1: significant improvements can be noted.



17.02.2006  
Ulcer 2: smaller deep grade 4 ulcer to left acetabulum.



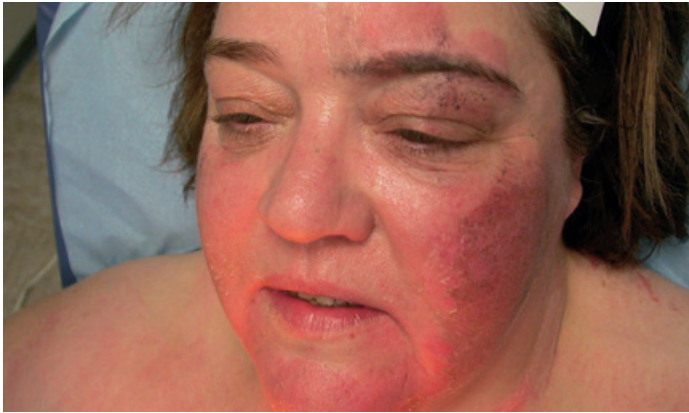14.04.2006  
Ulcer 2: significant improvements can be noted.



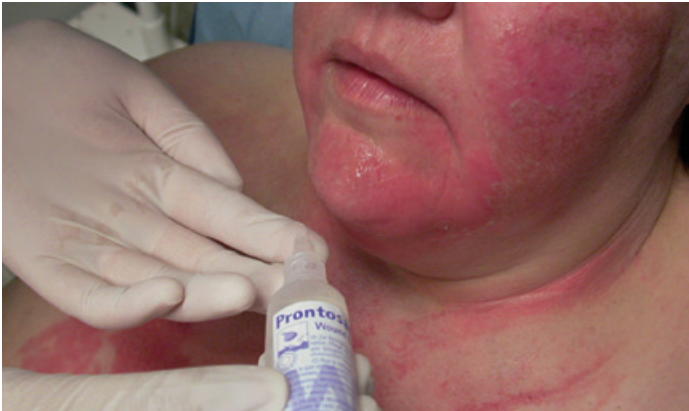17.03.2006  
Ulcer 2: wound shows signs of bleeding.

# Burn

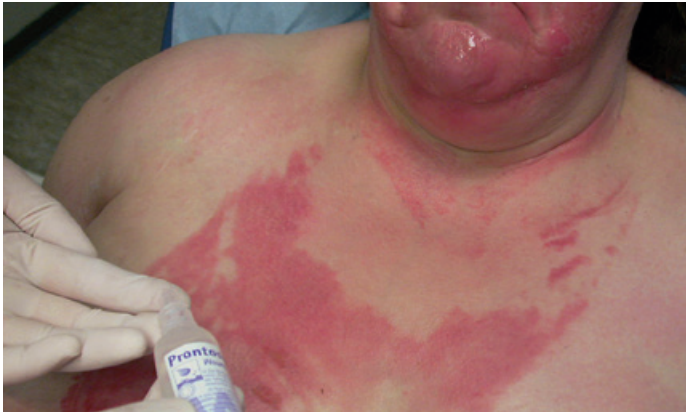Responsible person for treatment	Frans Meuleneire
Institution	AZ St Elisabeth, Zottegem, Belgium
Gender (female, male)	Female
Age of patient (year)	1970
Past medical history (PMH)	–
Medical treatment	–
Allergies	–
Wound diagnosis	2 <sup>nd</sup> degree burn
Localisation of wound	Face and breast
Age of wound	4 days
Previous treatment of wound	Mepilex® Transfer
Reason for treatment change	Encrusted burn wound
Dressing change frequency	Twice daily
Other products used	Mepilex® Transfer



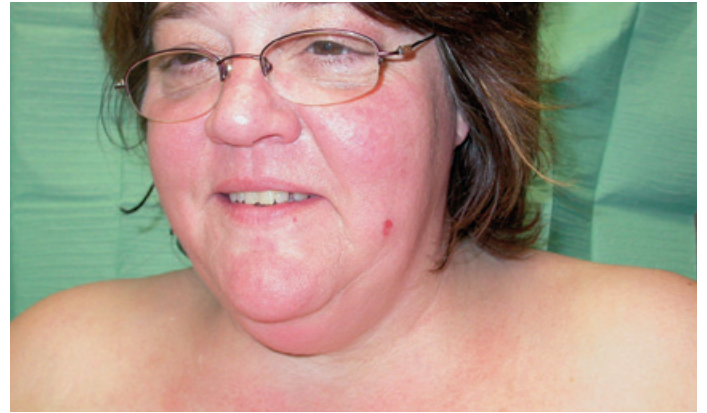09.06.2006  
Encrusted burn wound.



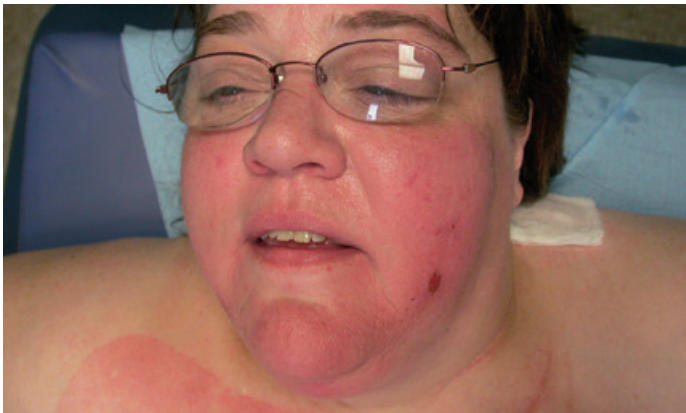09.06.2006  
Application of Prontosan® Wound Gel on facial burn.



09.06.2006  
Application of Prontosan® Wound Gel on chest burn.



16.06.2006  
Final result.

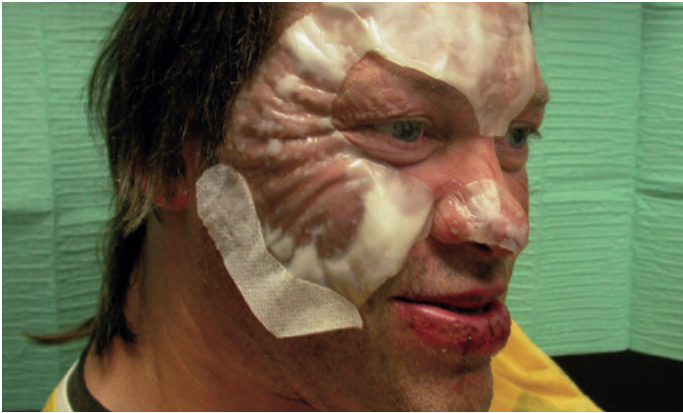

12.06.2006  
No need of secondary dressings.  
Satisfactory wound healing process.

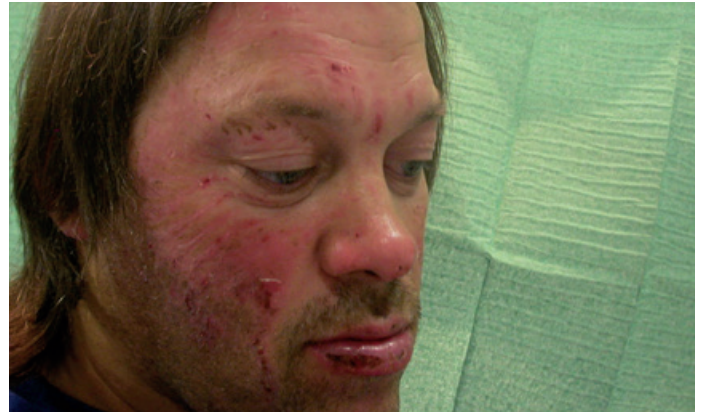# Burn

Responsible person for treatment	Frans Meuleneire
Institution	AZ St Elisabeth, Zottegem, Belgium
Gender (female, male)	Male
Age of patient (year)	1968
Past medical history (PMH)	–
Medical treatment	–
Allergies	–
Wound diagnosis	Second degree burn after gasoline explosion
Localisation of wound	Face
Age of wound	5 days
Previous treatment of wound	Hydrocolloid dressing
Reason for treatment change	–
Dressing change frequency	3 x day
Other products used	–

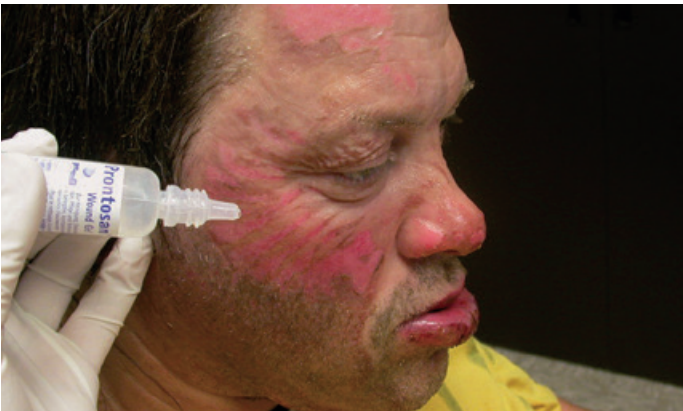



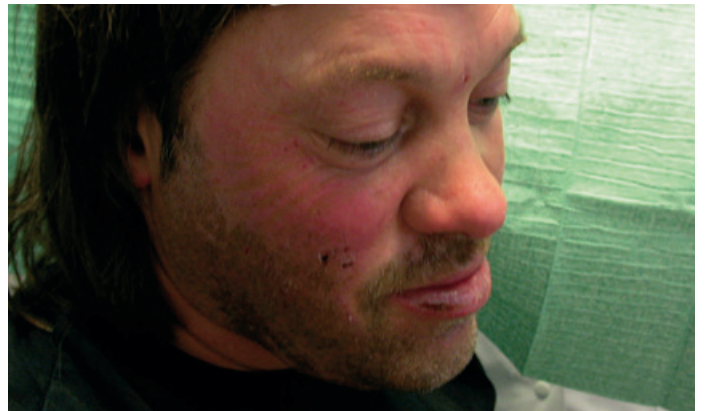
09.06.2006  
Hydrocolloid dressing applied to the wound.



13.06.2006  
Well-tolerated treatment.



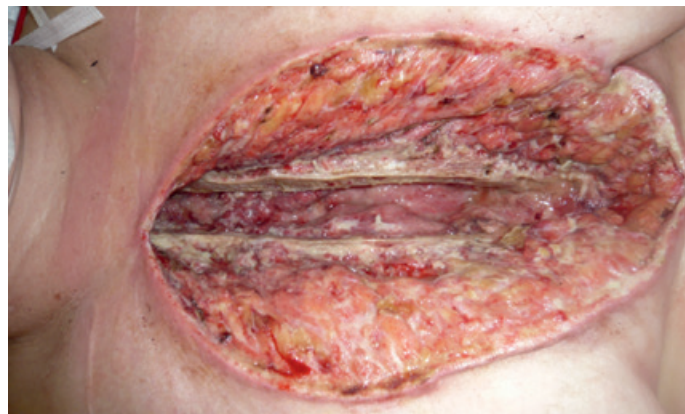09.06.2006  
Application of Prontosan® Wound Gel: 3 times daily.



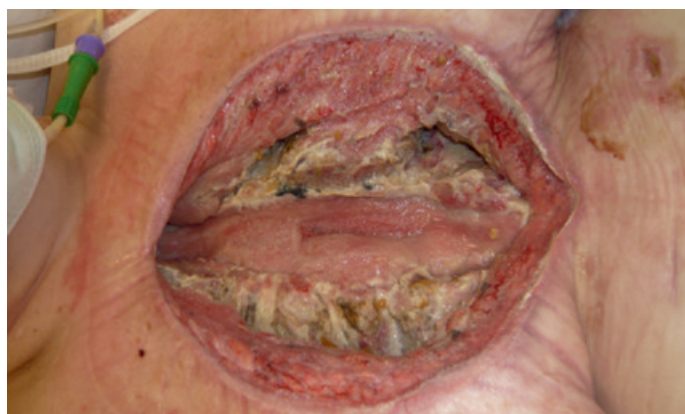16.06.2006  
Satisfactory results.

# Post-Operative Wound

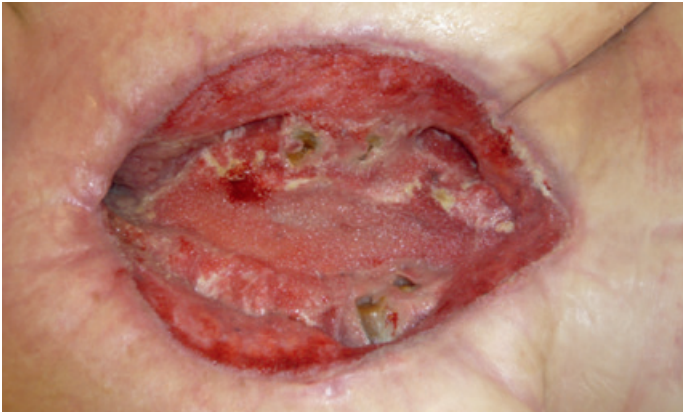Responsible person for treatment	Eveliena van der Kraats
Institution	St. Anothony's Hospital, Nieuwegein, Netherlands
Gender (female, male)	Female
Age of patient (year)	1951
Past medical history (PMH)	Postoperative open-heart surgery, hypertension, hypercholesterolemia, type II diabetes, malnutrition
Medical treatment	Floxapen, Ciprofloxacin, Oxycodone
Allergies	None known
<b>Wound diagnosis</b>	<b>Mediastinitis</b>
Localisation of wound	Sternum
Age of wound	Approximately 2 weeks old at first photograph
Previous treatment of wound	Wound debridement, negative pressure therapy, antibacterial gauzes, Eusol gauze
Reason for treatment change	Unknown
Dressing change frequency	Initially once per day and then three times per week
Other products used	Hydrofiber dressing, silicon foam dressing
Outcome (final comment)	The patient was discharged on January 15, 2011. The wound was significantly reduced and the patient was able to take care of it be herself after instruction. The wound pain disappeared, as did the pungent odor.



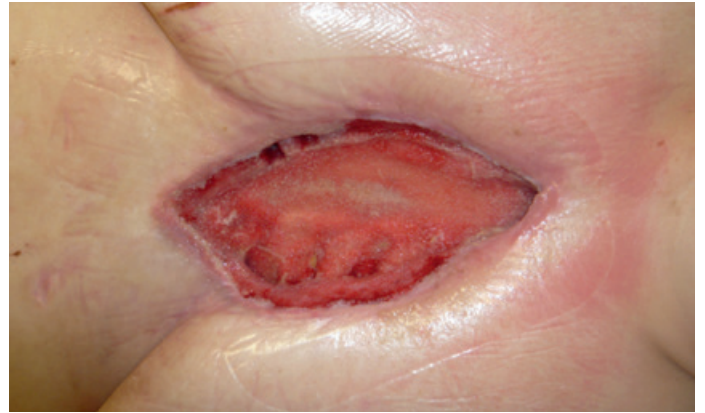08.02.2010  
Post-operative mediastinitis after debridement



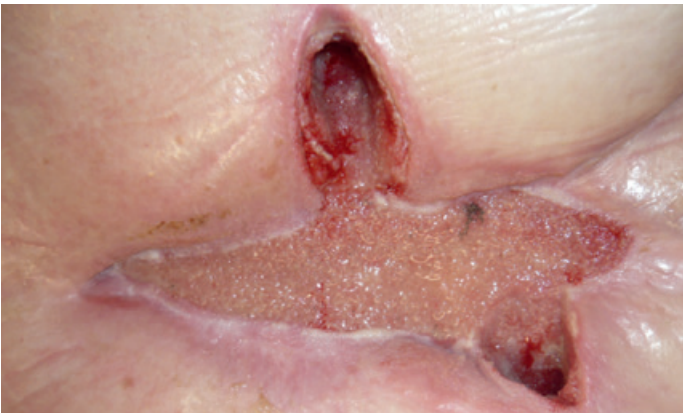30.03.2010  
Granulation tissue forming



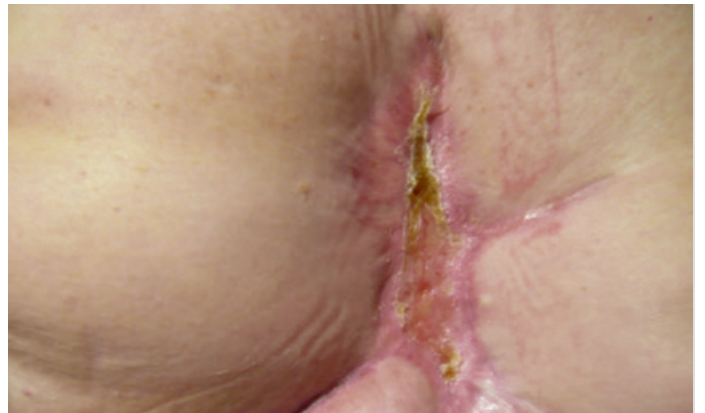
23.04.2010  
Undermined tissue in old cartilage cavities



25.05.2010  
Several debridements later



02.09.2010  
Treatment with Prontosan® started

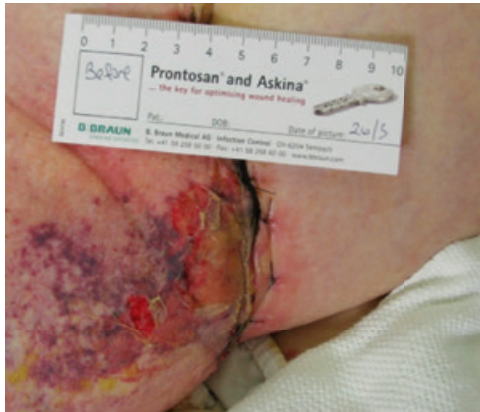

12.01.2011  
Wound almost completely healed

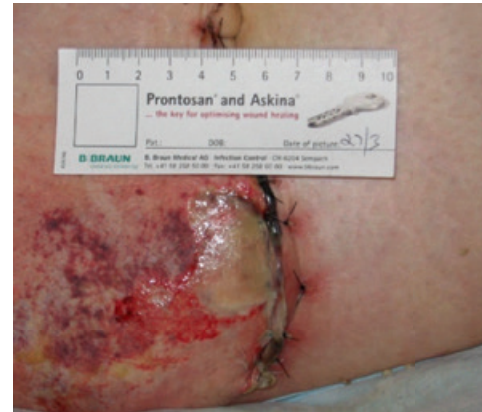# Post-Operative Wound

Responsible person for treatment	Matthew Dutton, Wound Care Clinical Nurse Consultant
Institution	The St. George Hospital, Kogarah, NSW, Australia
Gender (female, male)	Female
Age of patient (year)	1946
Past medical history (PMH)	Laparotomy and hernia repair
Medical treatment	–
Allergies	–
Wound diagnosis	Pressure ulcer to her abdominal apron (Post operatively – friction related)
Localisation of wound	Abdominal apron
Age of wound	–
Previous treatment of wound	–
Reason for treatment change	–
Dressing change frequency	Cleansed & packed with Prontosan® soaked gauze daily.
Other products used	In utilising Prontosan® as the wound cleanser on the wound bed in this situation initially aided in demarcating a previously unknown area of devitalised tissue then aided in cleansing a large abdominal cavity within a minimal time frame – Prontosan® solution provided a fast simple solution for wound cleansing.
Outcome (final comment)	Use of Prontosan® for this patient shortened an inpatient stay in Hospital.

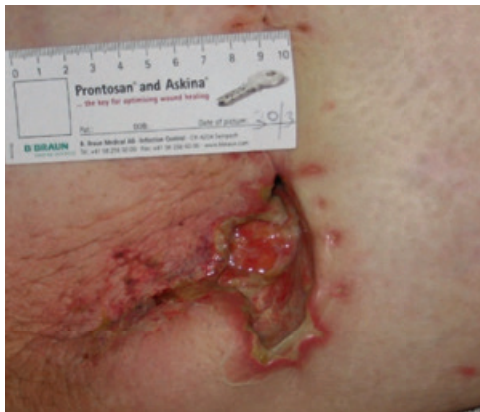



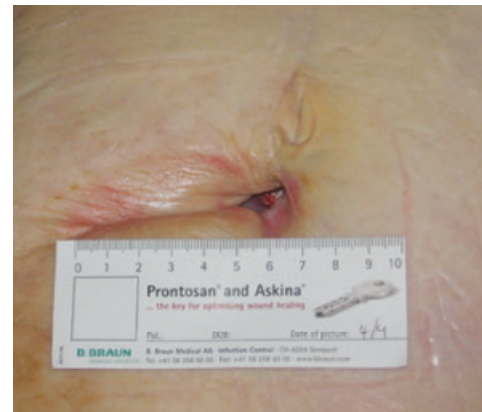Day 1  
The wound was covered with 95% thin slough, moist, mild serous exudate, nil odour and some peri-wound oedema.



Day 2  
The entire wound began to demarcate into grey dead tissue.



Day 4  
After being MRSA positive, the wound was cleansed and packed with Prontosan® soaked gauze daily.

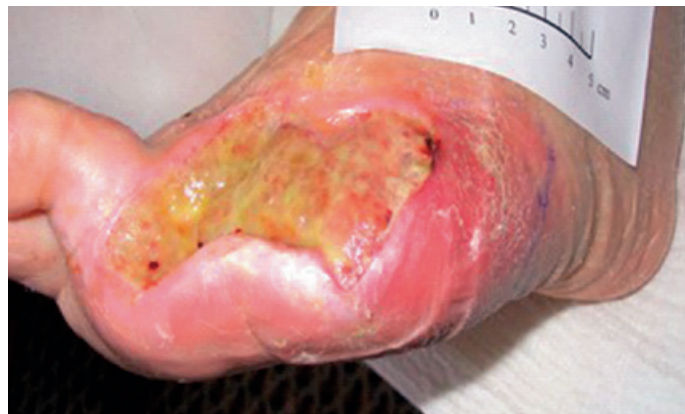

Day 188  
Within 3 days the wound was clean enough to use topical negative pressure therapy (TNPT) and within 7 days the patient was discharged home. **Prontosan®** was used up until day 60 when it was replaced with normal saline for cleansing.

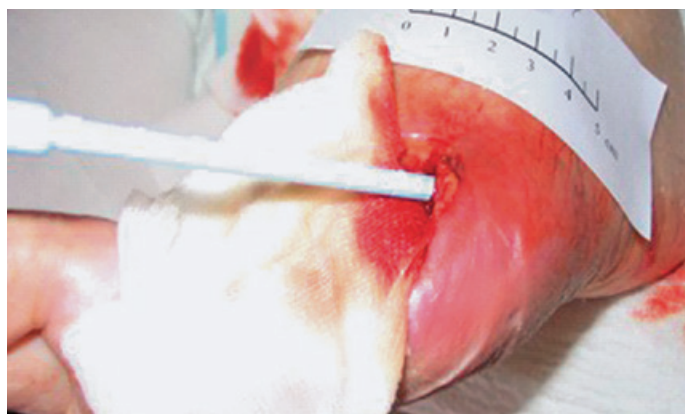


# Diabetic Ulcer

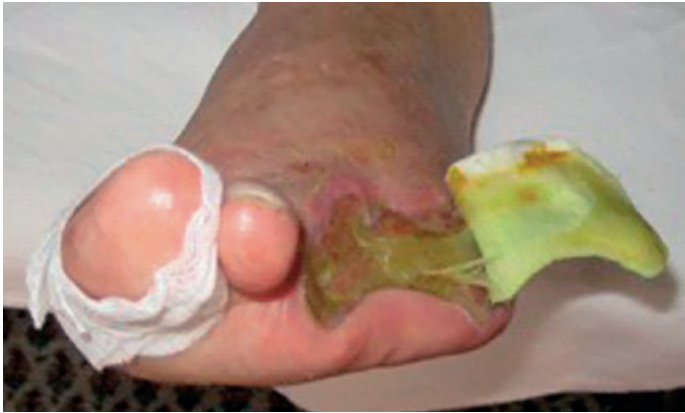Responsible person for treatment	Department of Visceral Surgery
Institution	Kempton Clinic, Germany
Gender (female, male)	Male
Age of patient (year)	73
Past medical history (PMH)	Peripheral Arterial Occlusive Disease (PAOD) stage IV, diabetes mellitus, polyneuropathy
Medical treatment	–
Allergies	–
Wound diagnosis	Diabetic Foot Syndrome (DFS)
Localisation of wound	Amputation wound D3 – D5, left forefoot
Age of wound	3 weeks
Previous treatment of wound	Ointment gauze
Reason for treatment change	Stagnation, infection
Dressing change frequency	Once daily
Other products used	–



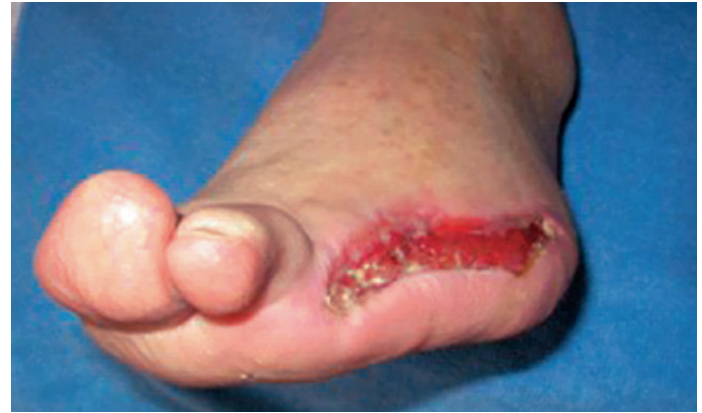16.07.2006 : Status post amputation D3 – D5 left forefoot. Wound aspect: sloughy, clearly discernible redness and swelling of entire forefoot. Pain upon pressure at the lateral edge of foot; wound covered in detritus. Patient supplied with pressure-relief shoe.



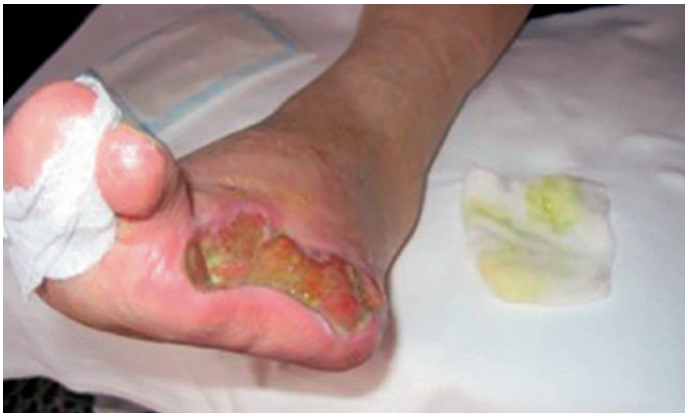16.07.2006  
Wound pocket at lateral edge of wound opened at a depth of 3 cm. Procedure: rinsed with Prontosan® Wound Irrigation Solution, wound pocket loosely packed with Sorbsan® Ribbon then saturated with Prontosan® Wound Irrigation Solution and covered with an Askina® pad. Change of dressing every day plus oral antibiotic.



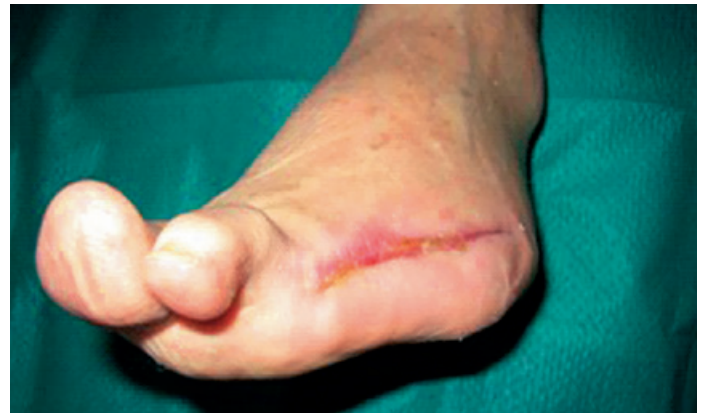18.07.2006  
Signs of inflammation markedly reduced; wound now dressed with Prontosan® Wound Gel together with Sorbsan® Plus (cut to size of wound) and covered with Askina® pad; change of dressing once a day.



01.10.2006  
Wound showing no signs of irritation; wound granulating; change of dressing now with Prontosan® Wound Gel and Askina® Touch. Change of dressing every three days.



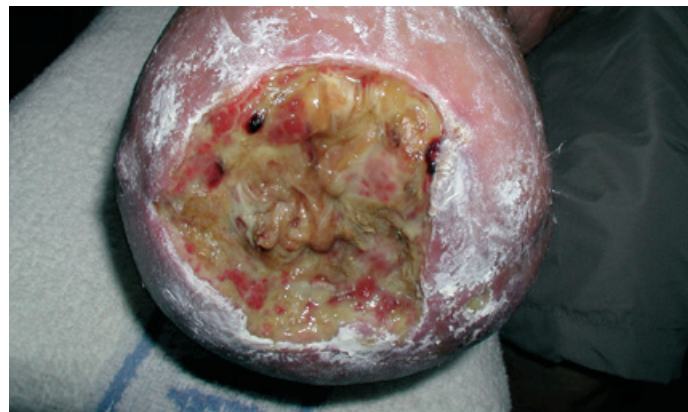23.07.2006  
Signs of inflammation abated, detritus is dissolving. Change of dressing according to following procedure: completely saturate an Askina® gauze compress with Prontosan® Wound Irrigation Solution, leave for 15 minutes then wipe wound clean; change of dressing as described above.



24.11. 2006  
Edges of wound showing no signs of irritation. Wound is in the epithelialisation phase. Keratosis removed consistently; rehabilitation centre; patient issued with shoes made of special leather for diabetic patients.

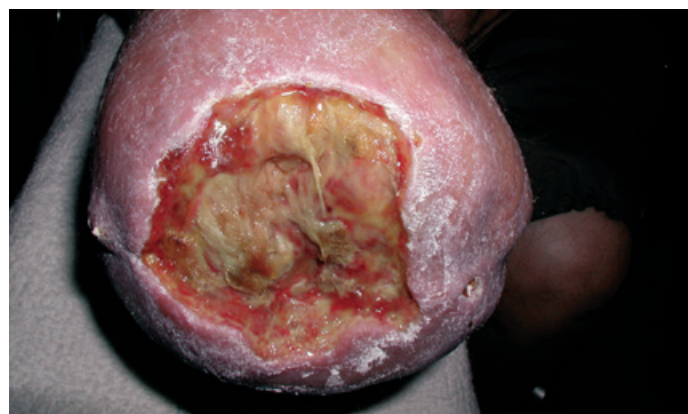# Other

Responsible person for treatment	Eric Roovers
Institution	ZNA Middelheim, Lindendreef 1, 2020 Antwerp, Belgium
Gender (female, male)	Male
Age of patient (year)	1927
Past medical history (PMH)	Hyperacute ischemia right lower leg
Medical treatment	–
Allergies	Unknown
Wound diagnosis	Necrosis, heavy exudation
Localisation of wound	Right lower leg amputation wound
Age of wound	56 days
Previous treatment of wound	Various
Reason for treatment change	No improvement in wound using other methods
Dressing change frequency	Twice daily
Other products used	Various



25.09.2006

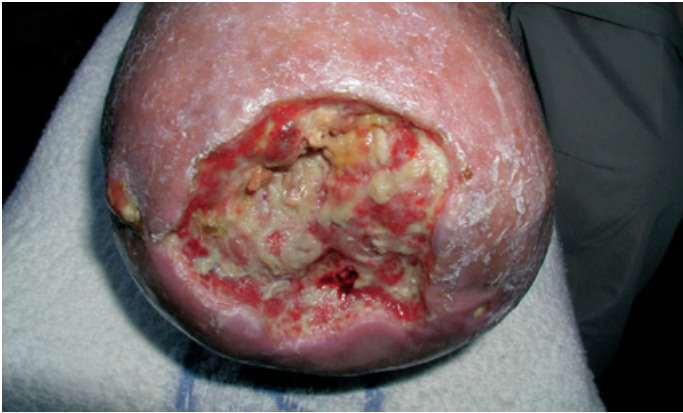Persistent necrosis, start Prontosan® Wound Irrigation Solution 2 times a day (moisturise compress, Prontosan® Wound Irrigation Solution remains in place until next bandage change), culture.



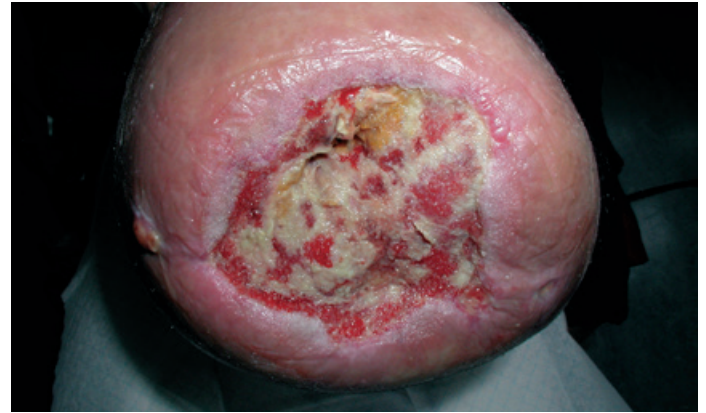03.10.2006

Favourable evolution, further treatment.

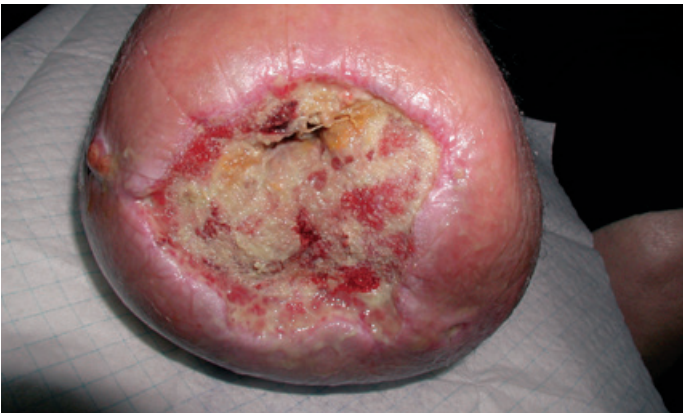



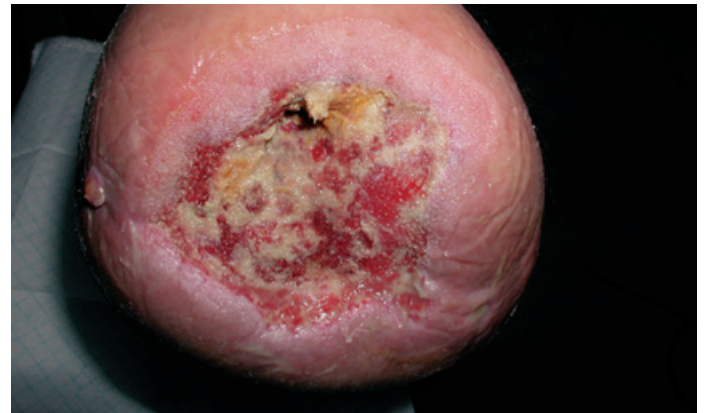11.10.2006  
Start V.A.C.-therapy.



18.10.2006  
Further V.A.C.-therapy.



16.10.2006  
Further V.A.C.-therapy, stop Prontosan® Wound Irrigation Solution.

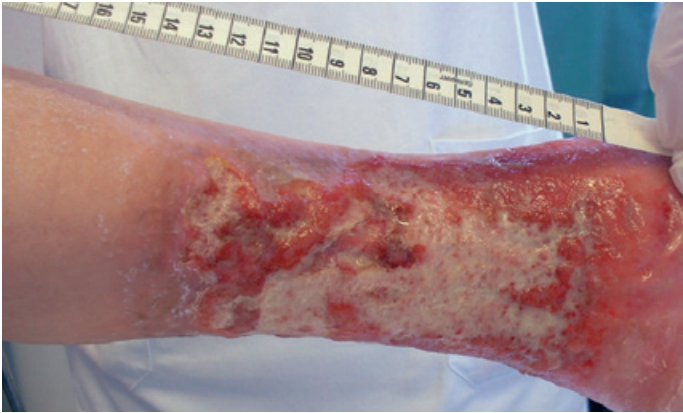

23.10.2006  
Further V.A.C.-therapy.

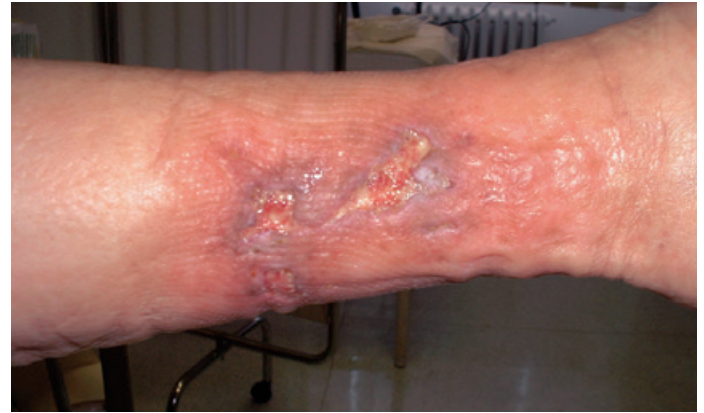# Other

Responsible person for treatment	Ornella Forma
Institution	Centro di Vulnologia, Azienda Ospedaliera Macchi, Varese, Italy
Gender (female, male)	Female
Age of patient (year)	1984
Past medical history (PMH)	Diabetic, iron-deficiency anaemia
Medical treatment	Insulin, iron
Allergies	None
Wound diagnosis	Mixed venous and arterial components, diabetic
Localisation of wound	Lower third, left leg
Age of wound	7 years
Previous treatment of wound	No progress with conservative treatment
Reason for treatment change	Due to heavy exudation and huge bacterial load the started alginate treatment has been changed to a hydroalginate treatment
Dressing change frequency	Every two days
Other products used	Polyurethane with silver ions, collagen + COR
Outcome (final comment)	Resolution of lesion thanks to combination of Prontosan® Wound Irrigation Solution and various types of products

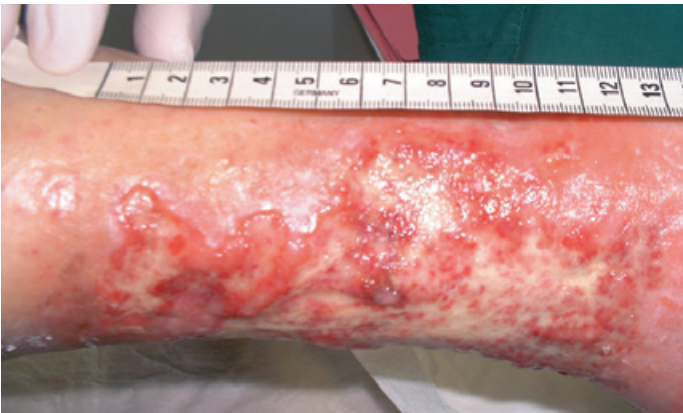



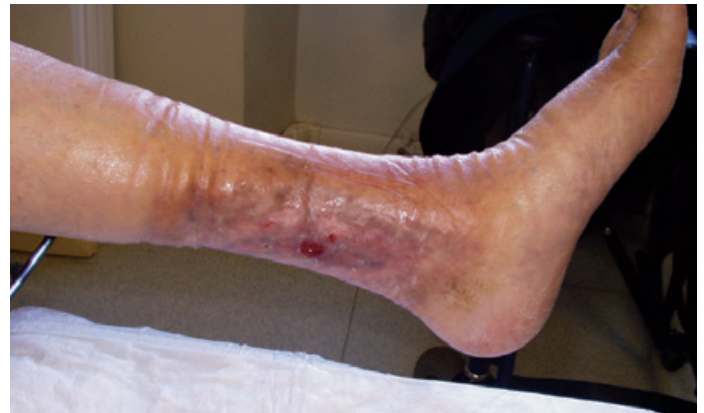24.03.2006  
Severe hyperaemia of surrounding skin, intense burning sensation.



10.05.2006  
Re-epithelialisation phase continues with Prontosan® Wound Irrigation Solution even if superficial + collagen with COR.



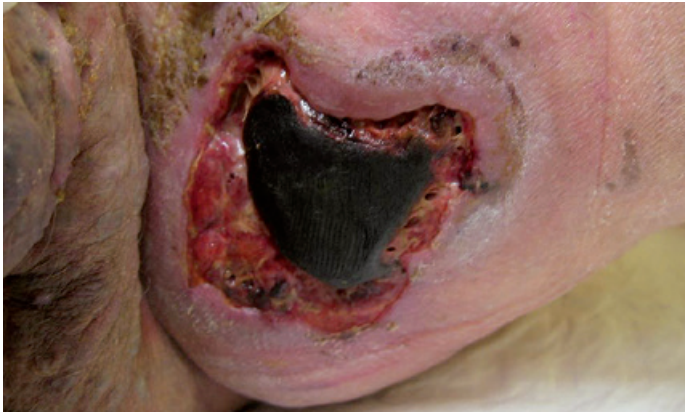07.04.2006  
Prontosan® Wound Irrigation Solution has significantly reduced the hyperaemia, fibrin and burning sensation subsided + polyurethane with silver ions.



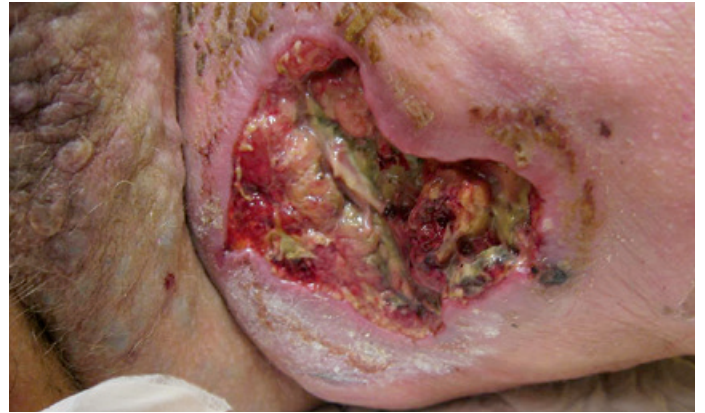22.05.2006  
Wound becomes almost healed.

# Other

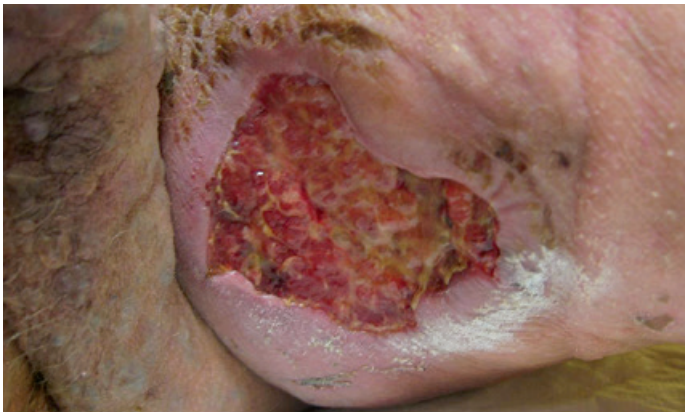Responsible person for treatment	Patricia van Mierlo (Nurse Practitioner)
Institution	UMC St Radboud Nijmegen, Netherlands
Gender (female, male)	Male
Age of patient (year)	1966
Past medical history (PMH)	Conginital AV-malformation; lower leg amputation (left) , compensatio cordis, hypertension
Medical treatment	Embolisation AV-malformation
Allergies	–
Wound diagnosis	Necrosis after alcohol embolisation AV-malformation
Localisation of wound	Left upper leg (groin)
Age of wound	4 weeks
Previous treatment of wound	Tap water cleansing, hydro-fibre with silver and foam dressing
Reason for treatment change	To soak necrosis, better cleansing wound
Dressing change frequency	Once daily
Other products used	Hydro-fibre with silver and foam dressing
Outcome (final comment)	After 1 week the necrosis could be taking out. After 2 weeks the wound was clean and less deep.



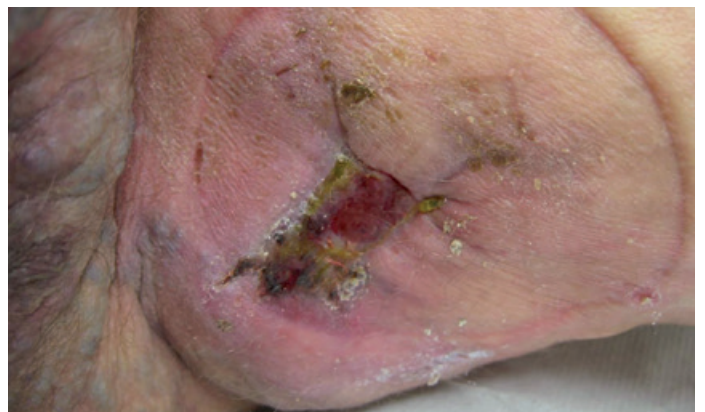03.09.2007  
Necrosis in wound 4 weeks after embolisation



10.09.2007  
Necrosis taking out one week after start using Prontosan® Wound Irrigation Solution



17.09.2007  
One week after removing necrosis

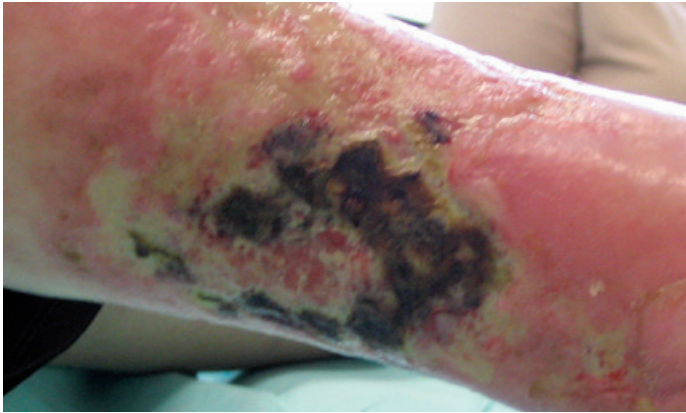

26.11.2007  
Wound is clean and almost closed

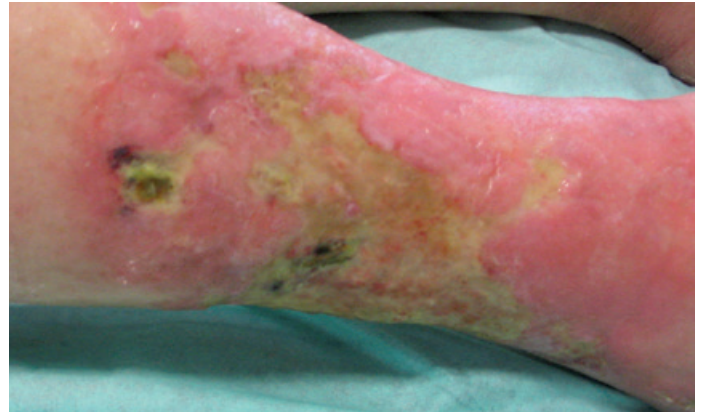
# Other

Responsible person for treatment	Ronny Manupassa
Institution	CWZ Nijmegen, Netherlands
Gender (female, male)	Female
Age of patient (year)	1921
Past medical history (PMH)	Chronic Venous and arterial insufficiency
Medical treatment	Balloon angioplasty
Allergies	Aquacel Ag and micanozolnitraat
Wound diagnosis	Chronic Ulcer
Localisation of wound	Left and right lower leg
Age of wound	4 months
Previous treatment of wound	Alginate and Gel
Reason for treatment change	No improvement, lots of pain and risk of amputation.
Dressing change frequency	Daily
Other products used	-
Outcome (final comment)	Significant increase of wound healing time. Amputation cancelled.

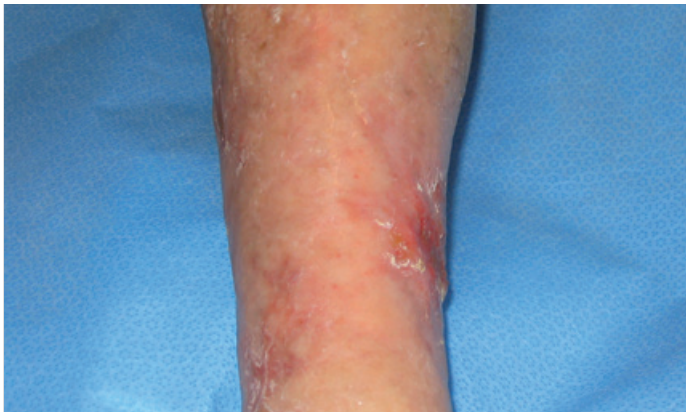



25.07.2007  
Necrosis of the skin, severe arterial and venous problems. Amputation discussed. Start treatment Prontosan®.



10.08.2007  
Significant improvement. Prontosan® Gel solved the necrosis. Patient mentioned relieve of pain. Amputation cancelled.

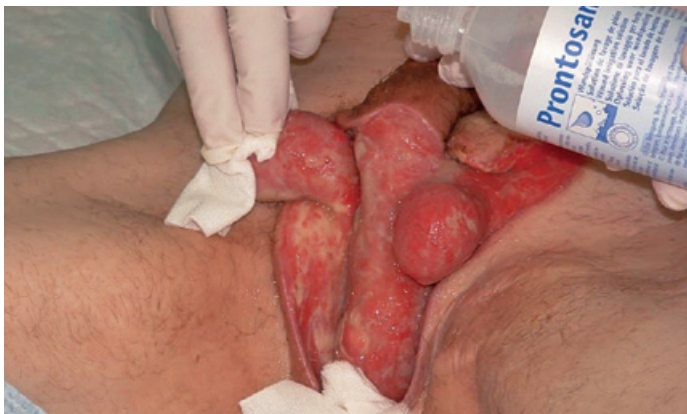

20.02.2008  
Significant wound area reduction

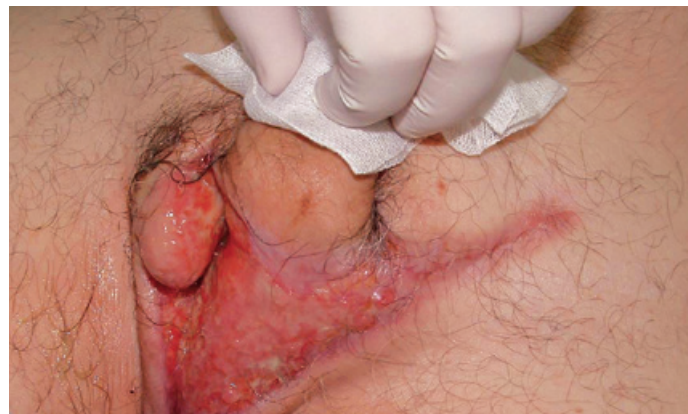

# Other

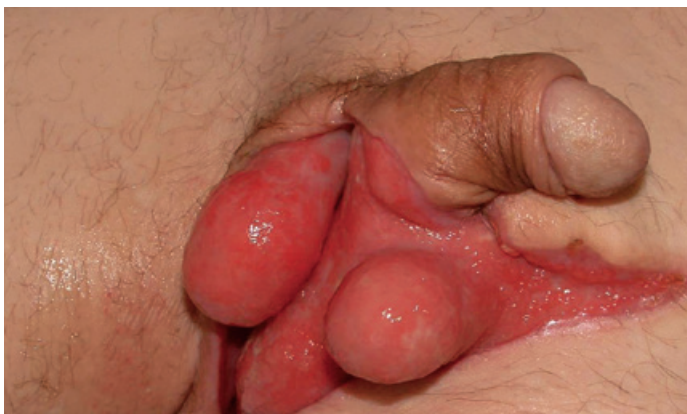Responsible person for treatment	Clara Ventolila
Institution	Hosp. Universitario de Puerto Real, Cádiz, Spain
Gender (female, male)	Male
Age of patient (year)	1948
Past medical history (PMH)	Fournier gangrene: necrotising infection soft tissue (scrotum,...)
Medical treatment	Antibiotics, analgesics...
Allergies	None
Wound diagnosis	Genital and anogenital region gangrene, deep and communicating purulent wounds on the back. Pain
Localisation of wound	Back and anogenital area
Age of wound	2004
Previous treatment of wound	1 month at hospital under different medical treatments
Reason for treatment change	None improvement of the wound and wound infection
Dressing change frequency	Every day
Other products used	Prontosan® Wound Gel, Askina® Transorbent, Sorbsan®, Askina® Calgitrol Ag
Outcome (final comment)	Wound improvement over 8 month



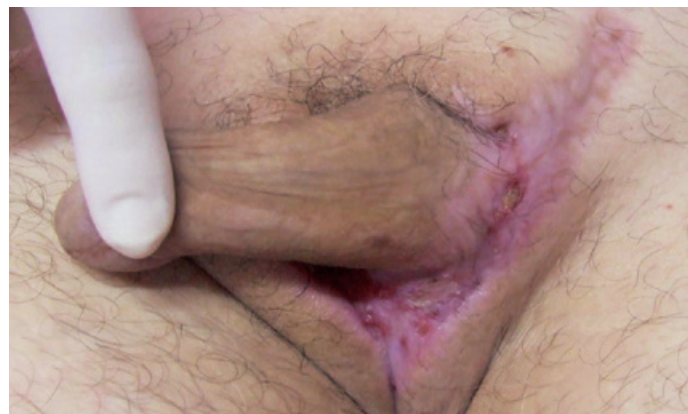11.11.2005  
Infected wounds in genital, anogenital region and the back.  
Rinsing with Prontosan® Wound Irrigation Solution. Application of Prontosan® Wound Gel + Sorbsan® + Askina® Sorb for debridement.



14.01.2006 : Significant wound area reduction at the genital area with good granulation and epithelialisation tissue. Wound on the back: after a period of treatment out of the hospital surgical debridement was necessary: Prontosan® Wound Irrigation Solution and Prontosan® und Gel + Askina® Calgitrol Ag + Askina® Transorbent.



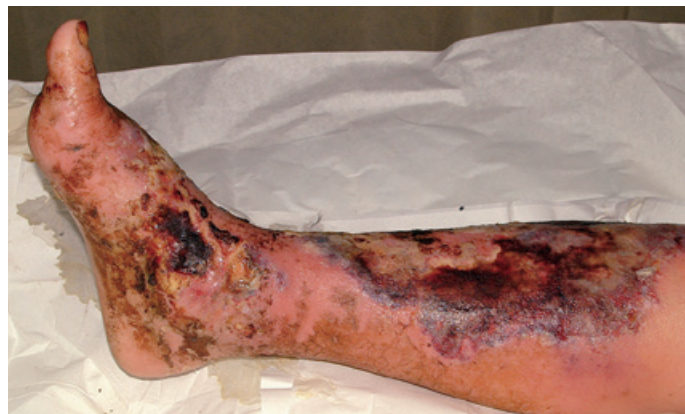23.11.2005  
Wound aspect after 12 days under same treatment. Wound cleansing and wound infection treatment.



07.07.2006  
Final evaluation: genital area: significant reduction in wound area and good granulation tissue. Wound on the back: after surgical debridement and wound treatment with Prontosan® Wound Irrigation Solution / Prontosan® Wound Gel + Askina® Calgitrol + Sorbsan and Askina® Transorbent significant reduction in wound area.

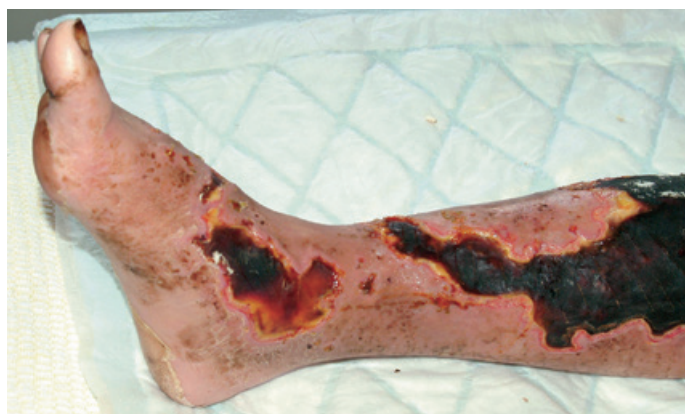# Other

Responsible person for treatment	Aisling Roberts, Vascular Nurse Specialist
Institution	The Great Western Hospital, Swindon, United Kingdom
Gender (female, male)	Male
Age of patient (year)	–
Past medical history (PMH)	Swollen lower leg, suspected cellulitis daily i.v. antibiotics for 2 weeks but further deterioration. Biopsy performed: T cell lymphoma
Medical treatment	Chemotherapy and complex wound management for the ulcer
Allergies	n/a
Wound diagnosis	Full complement of pedal pulses and a brisk capillary refill time, although the ulcer was necrotic
Localisation of wound	Knee cap to malleolus on the right leg
Age of wound	Presented in hospital 07. 10. 2005
Previous treatment of wound	Surgical debridement, V.A.C.-therapy, larve, topical silver dressings, MMP's etc.
Reason for treatment change	Wound colonised with MRSA and remained static for 6 months.
Dressing change frequency	Not known
Other products used	Not known
Outcome (final comment)	Patient sustained an improved quality of life when pain and mobility improved



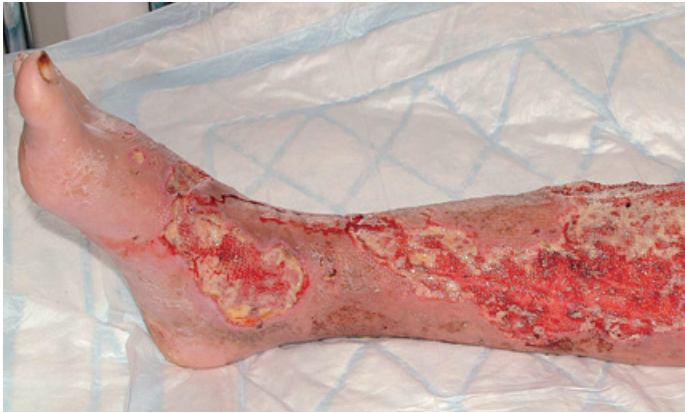07.10.2005

Presented in hospital with expected cellulitis.



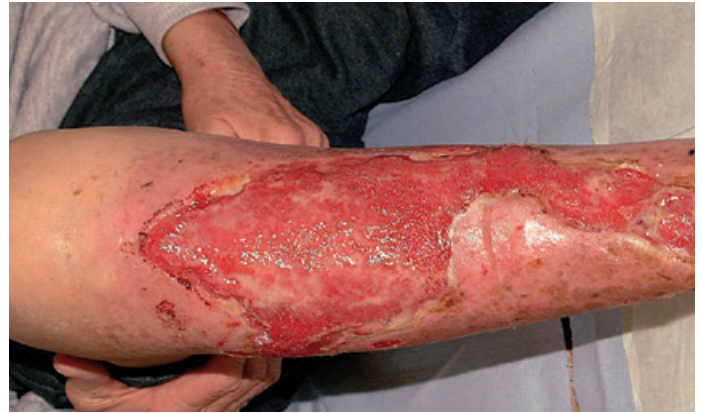28.10.2005

Referred to vascular department, biopsy planned.



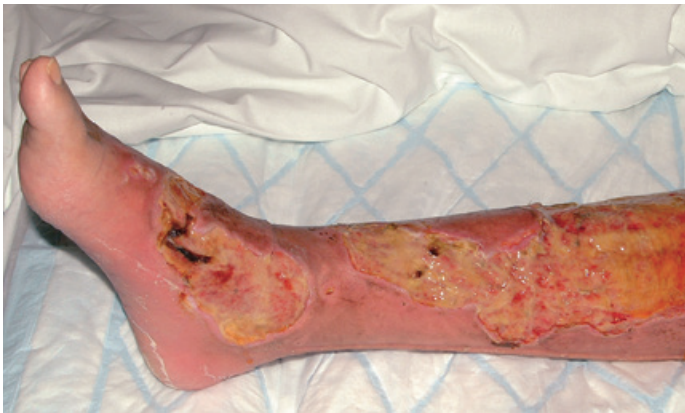31.10.2005

Biopsy showed aggressive peripheral T cell lymphoma, picture following surgical debridement of eschar following failed larve dressings.



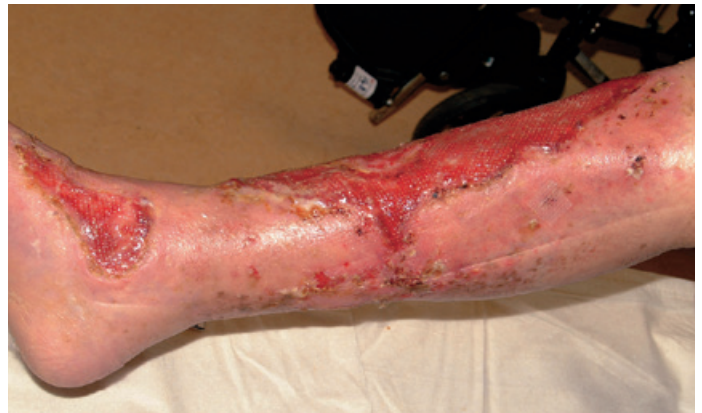03.04.2006

Chemo finished and recent bloods indicate cancer is gone. Wound improving with Prontosan® in use. Pain reduced and patient aiming for discharge.



14.12.2005

Chemo on going, wound critically colonised with Strep G & Staph. High pain, requiring morphine, trial V.A.C. with topical silver dressings to encourage granulation. Wound deteriorating leg becoming septic, risk of amputation or death.



23.05.2005

Patient remains in remission, remains free from MRSA.

